

Evaluation of *Ailanthus Excelsa* Leaves Extract against Chemically Induced Liver Damage

Suraj P. Nakhate

P.G., Student Dept. Biotechnology
New Arts Commerce and Science College
Wardha, (MS), India.
srjnakhate@gmail.com

Zubeen J. Hathi

Assistant Professor, Dept. Biotechnology
Agnihotri College of Science
Wardha, (MS), India.
hathizubeen@gmail.com

V. P. Ughade

Head, Dept. Biotechnology
New Arts Commerce and Science College
Wardha, (MS), India.
vaibhaviughade@gmail.com

Sandip S. Petare

Assistant Professor, Dept. Biotechnology
New Arts Commerce and Science College
Wardha, (MS), India.
petare_sandip@rediffmail.com

Abstract: *CCl₄ causes necrosis and congestion of central vein resulting hepatitis in Wistar rats. Biochemical investigation in such rats' shows elevated SGOT, SGPT, ALP and TB level up to 48.88, 31.88, 25 and 49% respectively, which is a consequence of functional destruction of liver cells.*

Methanolic leaves extracts of Ailanthus excelsa at 300 mg/kg and 600 mg/kg body weight shows remarkable reduction in SGOT, SGPT, ALP and TB level up to 82, 87 and 96% respectively while TB level increases up to 53%. While the Aqueous extract reduction level of SGOT, SGPT, ALP is about 76, 71, 83% respectively, while TB level increases up 59%. So, Methanolic extract of A. excelsa demonstrate solid hepatoprotective potential.

Keywords: *Ailanthus excelsa, Hepatotoxicity, CCl₄, Wistar rats, Necrosis and congestion.*

1. INTRODUCTION

Hepatitis is the term used for any condition where there is inflammation or necrosis of liver cells. Liver injury due to chemicals (synthetic drugs and pollutant) or infectious agents may lead to progressive liver fibrosis and ultimately, cirrhosis and liver failure [1]. Acute hepatitis is characterized by increase in aminotransferases coinciding with hepatocellular necrosis. Cholestasis is characterized by jaundice with a concurrent elevation in alkaline phosphatase, conjugated bilirubin, and glutamyl transpeptidase. Mixed-pattern drug induced liver injury includes clinical manifestations of both hepatocellular and cholestatic injury. In spite of tremendous advances in modern medicine no effective drugs are available, which stimulate liver functions and offer protection to the liver from the damage or help to regenerate hepatic cells [2]. In absence of reliable liver-protective drugs in modern medicine. Large number of medicinal preparations are recommended for the treatment of liver disorders [3]. Attempts are being made globally to get scientific evidences for these traditionally reported herbal drugs.

According to the United States Acute Liver Failure Study Group, Drug induced liver injury (DILI) accounts for more than 50% of acute liver failure, including hepatotoxicity caused by overdose of acetaminophen (APAP) is 39% and idiosyncratic liver injury triggered by other drugs is 13% [4] [5]. In most instances, DILI is initiated by the bioactivation of drugs to chemically reactive metabolites, which have the ability to interact with cellular macromolecules such as proteins, lipids, and nucleic acids, leading to protein dysfunction, lipid peroxidation, DNA damage, and oxidative stress. Additionally, these reactive metabolites may induce disruption of ionic gradients and intracellular calcium stores, which leads to reduction in energy production in mitochondria consequence results in cell death and possible cause of liver failure [6]. Metabolic functions, is a frequent target of a number of toxicants. The principal cause of chemical CCl₄

induced hepatic damage is lipid peroxidation and decreased activities of antioxidant enzymes and generation of free radicals [7]. In the view of above consideration the present study was made to evaluate the efficacy of methanolic and aqueous extracts of *Ailanthus excels* against CCl₄-induced hepatic damage in Wistar rats.

2. MATERIAL AND METHODS

2.1. Animal Models

Adult male Wistar albino rats weighing range 110-150 g strain originally brought from Shree Farms, Bhandara (M.S. India) are housed in cages kept at room temperature 23±2 °C and with a 12-h light/dark cycle, and with free access to rodent chow and tap water. The animal study is approved by the Institutional Animal Ethics Committee (IAEC), constituted for the purpose of control and supervision of experimental animals by Ministry of Environment and Forests, Government of India, New Delhi, India. Animals are naive to any drug treatments and experimentation at the beginning of all studies.

2.2. Plant Extract Preparation

The leaves and bark of *Ailanthus excelsa* are collected from the Gopuri, Garden, Wardha, (MS) India and authenticated from Prof. Acharya, Head, Dept. of Botany from J. B. College, Wardha, (MS), India and the voucher specimen is retained in laboratory for future reference. The dried coarsely powdered material of *Ailanthus excelsa* leaves are rendered moisture free and further separately extracted with Methanol, Ethyl acetate and Water by soxhlet extractor for 72 hours. The solvent is removed under reduced pressure and semisolid mass obtained dried in hot water bath. Advantage of soxhlet extractor over other procedure is continuous process instead of other procedure that involves batches of extraction.

2.3. Preliminary Phytochemical Screening

The preliminary phytochemical constituent (bioactive compounds) screening of fresh dried powder was carried out by standard procedures. Plants material thoroughly washed with water and are shade dried. Dried plant parts were powdered, stored in polythene zip lock bags at 30-32°C and proceed for phytochemical investigation.

2.4. Toxicity Studies

2.4.1. Carbon Tetrachloride Induced Liver Injury in Rats

Wistar albino rats were segregated into six groups viz. I, II, III, IV, V, and VI group possess six animals in each group. For the induction of hepatitis CCl₄ along vehicle (Olive oil v/v) 1 ml/kg has administered via Intraperitoneal route (IP) and the plant extracts via oral route. The significance of CCl₄ administered via intraperitoneal route in spite of other routes is to avoid capricious positive results because of possible injury of CCl₄ to other body organ. Group VIth served as normal control and received olive oil intraperitoneally. All other groups received CCl₄ (1ml/kg) 1st, 4th and 7th successive days. Group Vth animals were maintained as CCl₄ control group. Group Ist, IInd, IIIrd and IVth animals were treated with extracted plant drugs for 15 days. CCl₄ induces hepatotoxicity by metabolic activation; therefore it selectively causes toxicity in liver cells maintaining semi-normal metabolic function [8].

Nomenclature of animal groups according to experimental dosing of extract and CCl₄

Table1. Grouping of the animals for experimental studies

Group	Treatment
I	Methanolic extract 300 mg/Kg
II	Methanolic extract 600 mg/Kg
III	Aqueous extract 300 mg/Kg
IV	Aqueous extract 600 mg/Kg
V	CCl ₄ Control 1 ml/Kg
VI	Normal Control

2.5. Biochemical Study

Biochemical parameters viz. serum glutamic oxaloacetic transaminase (SGOT) and serum glutamic pyruvate transaminase (SGPT) are determined by Reitman and Frankel method

[9]. Reitman and Frankel method provides direct estimation of SGOT, instead of any inhibitory product formation during the assay and avoids cumbersome graph preparation. Serum alkaline phosphatase (ALP) was determined by King and Kings method [10]. King and Kings method employs direct cleavage of disodium phenyl phosphate by ALP with easy and simple colorimetric estimation which provides less incubation period and alternatively consumes less time. Total bilirubin (TB) measured by Malloy and Evelyn method [11]. It gives the accurate estimate of total bilirubin.

2.6. Histological Studies

After completing the successive three doses of CCl₄ on 1st, 3rd and 7th day, the Vth group i.e. CCl₄ control group was sacrificed and plant extract had continued being administered to remaining I, II, III and IV group. After 15 days by giving anesthesia rat had been made unconscious using chloroform and sacrificed. Blood sample was collected by puncturing heart for further biochemical studies and liver for anatomical investigations. Histological studies avail direct means of observe damage caused by CCl₄ and healing effect of plant drug extracted.

3. RESULTS AND DISCUSSION

3.1. Preliminary Phytochemical Screening

Table 2. Table given below shows the presence of following phytochemical

Sr. No.	Name of the Test	Observation	Result
1	Alkaloid	Orange color	+
2	Anthracene/Glycoloid	Purple or green	+
3	Flavonoids/Flavonols	Yellow colour	+
4	Phenolics/Tanins	Formation of white ppt	+

3.2. Biochemical Analysis

After sacrifice of rat blood sample was collected by puncturing heart, investigation was carried out viz. SGOT, SGPT, ALP, TB etc.

Table 3. Effect of extract of *A. excelsa* on biochemical parameters in CCl₄ induced Hepatotoxicity along with \pm standard deviation (SED).

Group	SGOT (IU/L)	SGPT (IU/L)	ALP (IU/L)	TB (mg%)
I	86 \pm 1	76.3 \pm 0.73	4.66 \pm 0.19	0.99 \pm 0.017
II	71.16 \pm 0.64	66.5 \pm 0.9	4.5 \pm 0.29	0.53 \pm 0.005
III	97 \pm 0.91	91.5 \pm 0.9	7.83 \pm 0.5	1.42 \pm 0.04
IV	74.5 \pm 0.9	85 \pm 0.81	5.16 \pm 0.28	0.66 \pm 0.008
V	103.66 \pm 1.49	102.5 \pm 1.15	8.66 \pm 0.2	2.33 \pm 0.04
VI	64.5 \pm 1.68	71.5 \pm 1.35	6.5 \pm 0.31	1.21 \pm 0.04

3.2.1. Serum Glutamate Oxaloacetate Transaminase (SGOT) Analysis

Serum glutamate oxaloacetate transaminase enzyme level was found to be increased after dysfunction of the liver. The level of SGOT gradually decreased when various doses of plant extract was given to the group I, II, III and IV. Table 3 shows that the order of SGOT analysis and graphical representation of the data is shown in figure 3.

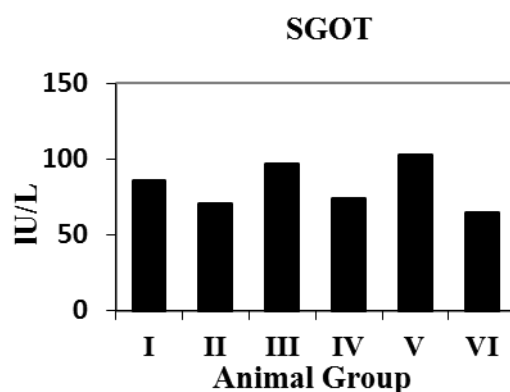


Fig1. Graphical representation of SGOT levels

Group VI normal control shows values of SGOT 64.5 ± 1.68 U/L and group V which was CCl_4 control shows 103.66 ± 1.49 U/L. which was significantly increased than normal values. Which might be due to CCl_4 induced dysfunction of liver. The level of SGOT in group II is less than I and III is less than IV. It means due to aqueous and methanolic extract the level of SGOT progressively decreased as concentration of extract increases.

3.2.2. Serum Glutamate Pyruvate Transamin-ase (SGPT) Analysis

Serum glutamate pyruvate transaminase enzyme level was increased after dysfunction of the liver. The level of SGPT was gradually decreased when various doses of plant extract were given to the group I, II, III and IV. Table 3 shows that the order of SGPT analysis and graphical representation of the data is shown in figure 4.

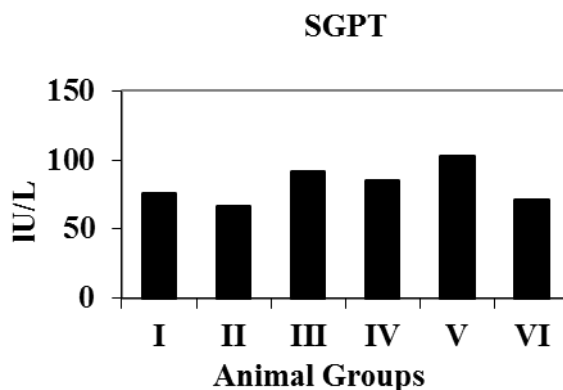


Fig2. Graphical representations of SGPT values

Group VI a normal control shows values of SGPT 71.5 ± 1.35 U/L and group V which is a CCl_4 control shows values 102.5 ± 1.15 U/L. which is much increased than normal value. Which might be because of CCl_4 induced dysfunction of liver. The level of SGPT in group II is less than I and in III is less than IV. As the concentration of herbal extract increases level of SGPT decreases. This alteration in level of SGPT might because of concentration and aqueous and methanolic extract preparation.

3.2.3. Alkaline Phosphatase (ALP) Analysis

The level of alkaline phosphatase enzyme increased after dysfunction of the liver. It is initially decreased when various doses of plant extract given to the group I, II, III and IV. Table 3 shows that the order of ALP analysis and graphical representation of the data is shown in figure 5.

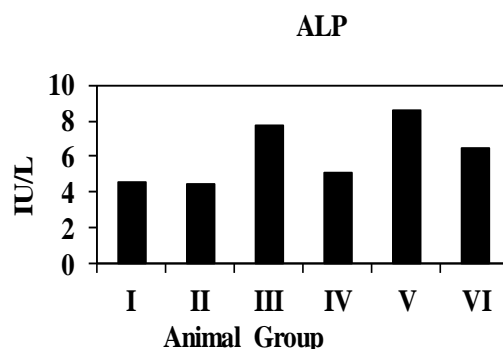


Fig3. Graphical representation of ALP

Group VI which is a normal control shows values 6.5 ± 0.31 U/L and group V which is a CCl_4 control shows 8.66 ± 0.2 U/L which is much increased than normal value. This happened due to CCl_4 induced dysfunction of liver. The level of ALP in group II was less than I and III was less than IV this alteration in the level of ALP is because of concentration screened as well as aqueous and methanolic extract preparation. The level of ALP decreased progressively as concentration of extract increases.

3.2.4. Total Bilirubin (TBL) Analysis

The level of alkaline phosphatase enzyme was increased after dysfunction of the liver. The level of TBL is gradually decreased when various doses of plant extract was given to the group I, II, III and IV. Table 3 shows that the order of TBL analysis and graphical representation of the data is shown in figure 6.

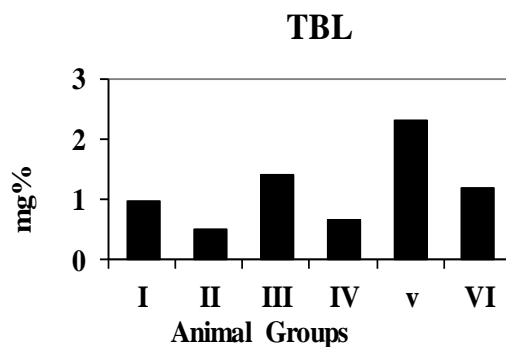


Fig4. Graphical representation of TBL

Group VI which is normal control shows values of bilirubin 1.21 ± 0.04 mg% and group V which is CCl_4 control shows 2.33 ± 0.04 mg% which was much more increased than normal value. This might be due to CCl_4 stimulated dysfunction of liver. The level of TBL in group II is less than I and III is less than IV. This alteration in the level of TBL is possibly due to concentration screened as well as aqueous and methanolic extract preparation. The level of TBL decreased progressively as concentration of extract increases.

3.3. Statistical Analysis

The statistical analysis is done by applying standard error of diffraction ($\pm\text{SED}$) to the experimental data. From this data the $\pm\text{SED}$ of biochemical parameters is found to be very low. Therefore the data is significant to the test.

3.4. Histological Analysis

The degree of gaining original shape and size of central vein and reduction of necrosis of cells is more evident in methanolic extract (600 mg/kg) treated rats as compare to other extract. Aqueous extract (600 mg/kg) treated rats reduces the necrosis and apoptosis as compared to (300 mg/kg) treated rat. Same results appeared with methanolic extracts. This means that as concentration increases the central vein gain its normal shape and size along with healthy hepatocytes regeneration reduced necrotic material and apoptosis.

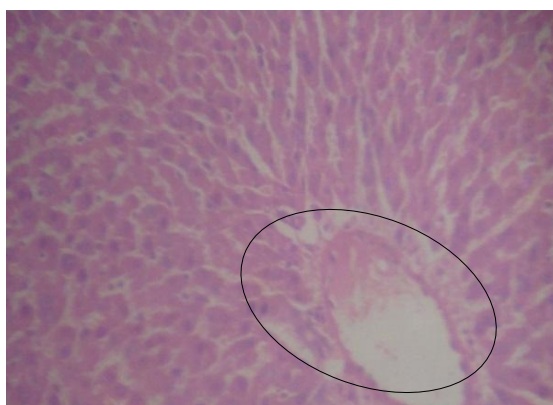


Fig5. The microphotograph shows maximum congestion, fibrosis of central vein, associated with necrosis, and apoptosis of hepatocytes due to CCl_4 . Accumulation fat, necrotic material and clear disappearance of blue colored nuclei from hepatocytes.

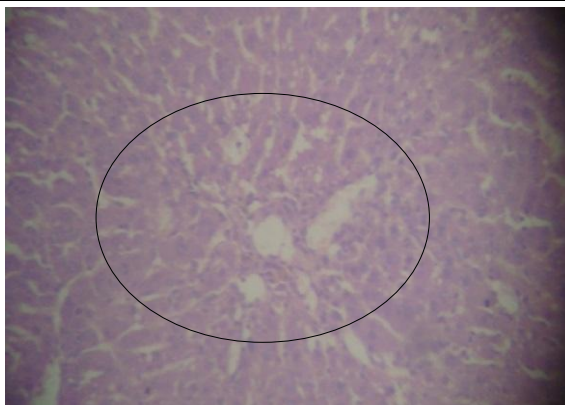


Fig6. *The microphotograph shows, as administration of methanolic extracts initiated, slit curing of congestion and fibrosis of central vein.*

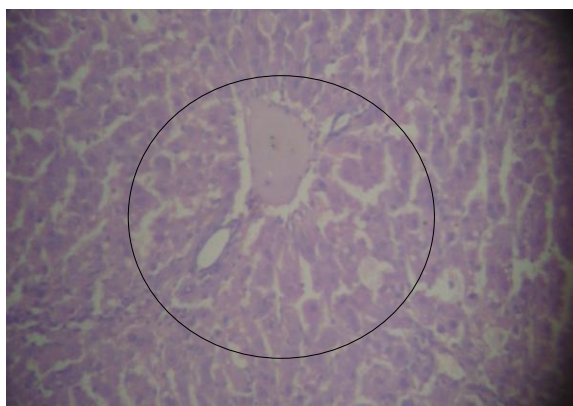


Fig7. *Microphotograph demonstrate hepato protective potential as slit curing of congestion and fibrosis of central vein with administration of aqueous extract.*

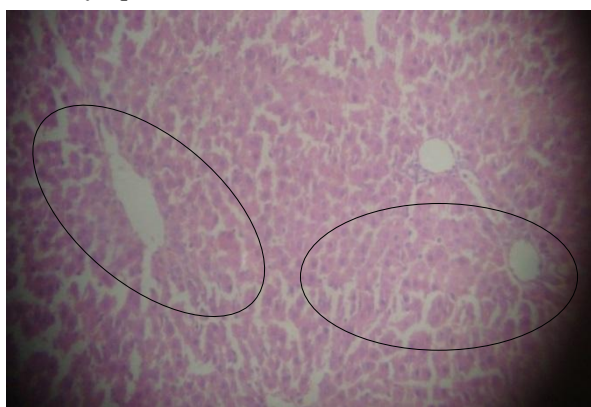


Fig8. *Microphotograph shows central vein regaining normal size and shape along with clearance of necrotic material.*

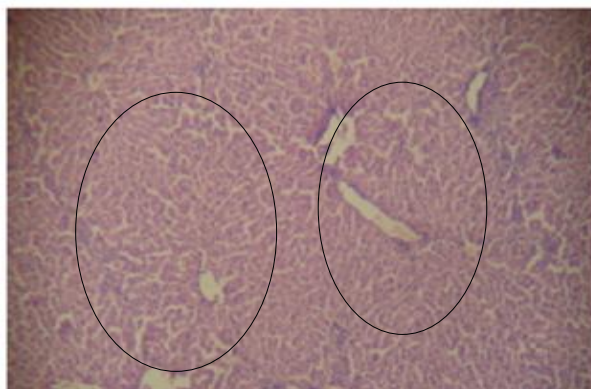


Fig9. *Microphotograph shows, As the concentration of methanolic extract increases with time duration regaining of normal size and shape of central vein along with appearance blue colored nuclei and also gradual regeneration of hepatocytes.*

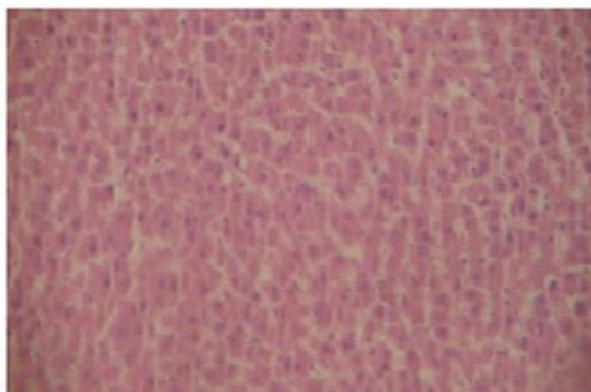


Fig10. Microphotograph shows the normal healthy hepatocytes and normal size and shape of central vein. Clear reappearance of blue colored nuclei in hepatocytes with clearance of apoptotic and necrotic material in specimen. Congestion and fibrosis is completely disappeared.

Carbon tetrachloride (CCl_4) is one of the most commonly used hepatotoxin [12], [13]. In present study, hepatotoxicity in albino Wistar rats was successfully developed by administering CCl_4 intraperitoneally. CCl_4 is bio-transformed by the cytochrome P-450 system in the endoplasmic reticulum to produce trichloromethyl free radicals which when combined with cellular lipids and proteins in the presence of oxygen form trichloromethyl peroxy radical, which may attack lipids on the membrane of endoplasmic reticulum faster than trichloromethyl free radicals. Thus, trichloromethyl peroxy free radicals leads to elicit lipid peroxidation, the destruction of Ca^{2+} , homeostasis and finally result in cell death [14]. Along with lipid peroxidation CCl_4 intoxication causes disruption and dissociation of polyribosomes on endoplasmic reticulum and thereby reducing the biosynthesis of proteins. Due to the damage caused to hepatic cells, the leakage of plasma causing an increased levels of hepato specific enzymes in serum. The hepatoprotective index of a drug can be evaluated by its capability to reduce the injurious effect or to preserve the normal hepatic physiological mechanisms, which have been induced by natural means and or by hepatotoxin. The measurement of SGPT, SGOT, and ALP levels serve as a mean for the indirect assessment of condition of liver. A high concentration of bilirubin in serum is an indication for increased erythrocyte degeneration rate. It also reflects the necrotic conditions of hepatocytes. The oral administration of aqueous and methanolic extracts (300 mg/kg and 600 mg/kg each) reduced the serum TB level. The histopathological studies are the direct mean for assessing the protective effect of the drug from liver injuries. The groups received CCl_4 alone, the damage of cells around the central vein were well evident. Whereas, the intensity of damage was found lesser in the studies involved pretreatment of aqueous and methanolic extracts. The results of the histopathological studies supported and well correlated with data obtained from evaluation of the biochemical parameters. Assessment of liver can be made by estimating the activities of SGOT, SGPT and ALP which are the enzymes originally present in higher concentration in cytoplasm. When there is hepatopathy, these enzymes leak into the blood stream in conformity with the extent of liver damage [15]. The elevated level of these entire marker enzymes observed in the group V CCl_4 treated rats in this present study corresponds to the extensive liver damage induced by toxin. The reduced concentrations of SGOT, SGPT, ALP and TB as a result of plant extract administration observed during the present study might probably due to the presence free radical scavenging activity of flavonoids in the extract [16]. The tendency of these marker enzymes to return towards a near normalcy in groups I-IV. *A. excelsa* leaves extract treated rats is a clear manifestation of anti-hepatotoxic effects.

4. CONCLUSION

Preliminary investigation of the phytochemical contents of *A. excelsa* leaves revealed that the leaves are rich in flavonoid and glycosides. *In vivo* treatment with *A. excelsa* leaf extract decreases the CCl_4 -induced lever damage resulted in elevation in biochemical parameters. Upon CCl_4 treatment, SGOT level increases up to 48.88%, SGPT level up to 31.88%, and ALP level by 25% and TB level increases by 49%. This means that functional destruction of liver cell in rat. In comparison between methanolic extract of 300mg/kg and 600 mg/kg the increased level of biochemical parameters such as SGOT reduces up to 82%, SGPT level up to 87%, ALP level by

96% and TB level decreases by 53%. As well as the aqueous extract reduces SGOT level up 76% to SGPT level up to 71%, ALP level by 83% and TB level decreases by 59%.

Along with cytological healing evidence observed under microphotograph. These findings suggest that the extract was effective in bringing about functional improvement towards normal state of hepatocytes. The possible mechanism of hepatoprotective activity of *A. excelsa* may be due to its free radical-scavenging and antioxidant activity, which may be due to the presence of flavonoids in the extract. The antioxidant activity of flavonoids can scavenge free radical and protect the cell membrane from destruction. Hence, the transaminases (SGOT/SGPT) may not leak into the blood from the necrotic hepatocytes. This finding indicates the efficacy of *A. excelsa* leaf extract as a hepatoprotective.

ACKNOWLEDGEMENTS

Authors are highly thankful for capturing microphotographs to Dr. Prof. Sunita Wagh, Head Department of Histopathology, Jawaharlal Nehru medical college Sawangi (M), Wardha Maharashtra, India.

REFERENCES

- [1] Anand B. S., Cirrhosis of liver, West J Med, 171, 110–5 (1999).
- [2] Chattopadhyay R. R., Ethnopharmacol, 89, 217 (2003).
- [3] T. K. Chatterjee, Medicinal Plants with Hepatoprotective Properties in Herbal Options. Books and Allied (P) Ltd. Calcutta, 2000, ch. 3, pp. 135.
- [4] Ostapowicz G., Fontana R. J., Schiodt F. V., Results of a prospective study of acute liver failure at 17 tertiary care centers in the United States,” Ann Intern Med. 137, 947 – 954 (2002).
- [5] Michael P. H., Cynthia, Mechanisms of Drug-Induced Liver Injury, The AAPS Journal, 8 (2005).
- [6] Russmann S., Kullak – Ublick G. A., Grattagliano I., Current Concepts of Mechanisms in Drug-Induced Hepatotoxicity, Current Medicinal Chemistry, 16, 3041-3053 (2009).
- [7] Rajan A. V., Shanmugavalli N., Umashankar V., Hepatoprotective effects of *Cassia tora* on CCl₄ induced liver damage in albino rats, Indian Journal of Science and Technology, 2(3), (2009).
- [8] Mujumddar A. K., Upadhye A. S., Effect of *Azadirachta indica* leaf extract on CCl₄ Induced hepatic damage in albino rats, Ind. J. Pharm. Sci, 60, 363 (1998).
- [9] Reitman S., Frankel A. S., Colorimetric method for determination of serum glutamic oxaloacetic and glutamic pyruvic transaminase, American. J. Clinical Pathology, 28, 53-63 (1959).
- [10] King P. R., King E. J., Determination of Serum Alkaline Phosphatase, J. Clin. Path., 7, 132-136, (1954).
- [11] Malloy H. T., Evelyn K. A., The determination of bilirubin, J. Biol. Chem, 119, 481-485, (1937).
- [12] Sane R.T., Kuber V.V., Hepatoprotection by *Phyllanthus amarus* and *Phyllanthus debilis* in CCl₄ Induced Liver Dysfunction,” Current Science, 68, 1243-1246 (1995).
- [13] Pingale S. S., Hepatoprotection by *Acacia catechu* in CCl₄ Induced Liver Dysfunction, International Journal of Pharmaceutical Sciences Review and Research, 5, 150-154 (2010).
- [14] Opoku A. R., Ndlovu I. M., Terblanche S. E., In vivo hepatoprotective effects of *Rhoicissus tridentata* sub sp. cuneifolia, a traditional Zulu medicinal plant, against CCl₄-induced acute liver injury in rats. Sou. Afr. J. Bot, 73, 372–377 (2007).
- [15] Nkosi C. Z., Opoku A. R., Terblanche S. E., Effect of pumpkin seed (*Cucurbita pepo*) protein isolate on the activity levels of certain plasma enzymes in CCl₄-induced liver injury in low-protein fed rats, Phy. the. Res. 19, 341–345 (2005).
- [16] Tapas A. R., Sakarkar D. M., Flavonoids as Nutraceuticals: A Review, Tropical Journal of Pharmaceutical Research, 7 (3), 1089-1099, (2008).

AUTHORS' BIOGRAPHY



Suraj P. Nakhate, is a Student PGDT of biotechnology of New arts commerce and science college, Wardha MS. He has a good depth of knowledge in the field of medical biotechnology. He is found to be skillful towards observation and interpretation of results during study. He is sincere and hardworking.



V. P. Ughade, is a Microbiologist from Rashtrasnat Tukdoji Maharaj Nagpur, University, Nagpur (MS). Since 2002 she is serving /working in the field of Medical Microbiology through teaching learning process and perusing her doctorate focusing the research area on mycological flora of Melghat forest rich in biodiversity and recognized nationally for Tiger Reserve Project, Amravati, Maharashtra. Author has published and presented many research papers in journals of national and international standard.



Zubeen J. Hathi, is a biochemist had a master degree from RTM Nagpur University, Nagpur in 2006. Since then working as a Assistant Professor. Engaged in doing cutting edged research in medical biochemistry.



Sandip S. Petare, is Master in biotechnology, qualified national eligibility test for assistant professorship. He has presented and published several research papers in journals and conferences of national and international repute. He is actively working on drug development against lymphatic filariasis and keep keen interest in the field of drug designing, bioinformatics, wildlife forensic etc.