

Acute Abdomen in a Patient with HIV, a Challenge for the Surgeon. Systematic Review and Case Report of Intra-Abdominal Tuberculosis

Flores-Almanza José¹, Ortiz-Fernández Daniela Naomi¹, López-Márquez Arturo Amed¹, Juárez-Hernández Carolina¹, Cabrera-Gallegos Victor Salvador¹, Armendariz-Rodríguez Andrés², Robles Mendez Hernandez Alberto^{3*}

¹Escuela Nacional de Medicina y Homeopatía, Instituto Politécnico Nacional, Mexico City, Mexico.

²Facultad de medicina, Universidad Nacional Autónoma de México, Mexico City, Mexico.

³Department of general surgery, Hospital Angeles Metropolitano, Mexico City, Mexico.

***Corresponding Author:** Robles Mendez Hernandez Alberto, Department of general surgery, Hospital Angeles Metropolitano, Mexico City, Mexico

Abstract

HIV is an infection of great relevance worldwide, since it has a close relationship with opportunistic infections, in which tuberculosis (Tb) stands out, being more frequent in its extrapulmonary forms. A case report is made of a 31-year-old patient with an acute abdomen with a recent HIV diagnosis

Keywords: HIV, tuberculosis, acute abdomen, casereport, surgery, intra-abdominal tuberculosis.

1. INTRODUCTION

Human immunodeficiency virus (HIV) is one of the most relevant treatable diseases in the last decades, at the same time represents an international difficulty. (1,2)

In Mexico, reported by the Direction of Epidemiological Surveillance of Transmissible Diseases (DVEET), incidence of HIV and the Acquired Immune Deficiency Syndrome (AIDS) until the 26th week of the 2020 were 4567, of which 2849 are for HIV and 1718 to AIDS. (3)

In the world its prevalence nearly to 37 million people with HIV, and a mortality of 1 million/year (4), this is disturbing because of lethality index. Since it starts at the beginning of the 80's decade until our days has caused more than 30 million deaths (4,5).

The problem of HIV lies in the affection to the immunological system of the human because it works with many mechanisms, various still unknown. The value of the helper T-cell (CD4+) decreases, producing a statement of immunodeficiency favoring the spread of many infections, mostly opportunistic. In developing countries, the patients they are usually detected with this kind of pathological

agents.

The risk of develop an opportunistic infection increase when the CD4+ counting is <200 cell/mm³, an absolute and differential count of CD4+ must be realized each 4 to 6 months after the antiretroviral treatment began, specifically in the patients with <300 cell/mm³. We must start the antiretroviral therapy notwithstanding of the CD4+count (7).

2. METHODS

Systematic qualitative review using data bases like Pubmed, Science Direct, Clinical Key and official statistics of the Health Secretary of Mexico and WHO. Including original and review indexed articles in English and Spanish. Case report of Mexico City, accomplished in a public hospital, following the ethical standards in relationship to the safety of the patient information.

3. TUBERCULOSIS AND HIV

Based on the survey, it was observed that even in 2021 after many years of scientific advances and the discovery of tuberculosis (Tb), it is still considered the main cause of mortality due to an infectious agent in the adult population (8). In 2015 there were

approximately 10.4 million new cases in the world, in that same year Mexico reported 2,125 deaths. The relevance of talking about Tb lies in the fact that 11% of patients with the infection coexist with HIV (9).

Tb is an infectious disease caused by the *Mycobacterium tuberculosis* complex, whose main transmission mechanism is the aerosols produced by an infected person while coughing, other transmission routes are the contact of dermal lesions with sick people or bovines with the infectious agent and the vertical infection "mother to child". A primary pulmonary focus generally occurs characterized by granulomatous necrosis. (10,11) There are 25-30% of patients who present extrapulmonary disease itself that makes timely diagnosis difficult, worsening the patient's prognosis (12).

In most cases, the extrapulmonary form occurs from the dissemination of a pulmonary focus

and can affect any organ of the body. It occurs mostly in states of immunosuppression. Worldwide, extrapulmonary tuberculosis cases represent 15% of the 7 million cases that were notified during 2018 (13,14).

Among the most important risk factors for developing extrapulmonary TB is immunodeficiency, which in most cases corresponds to an HIV infection (50% of HIV-positive patients with tuberculosis in the active phase who develop extrapulmonary manifestations), advanced age, female sex and in developed countries the presence of immigrants (15,16).

The most common forms of extrapulmonary tuberculosis are lymph node (30-40%), pleural (20%), genitourinary (14%), central nervous system (CNS) (7-12%), osteoarticular (11%), peritoneal (11%), cutaneous (0.5-2%), among others. (Fig. 1) (12, 17,18,19) Peritoneal and intestinal tuberculosis.

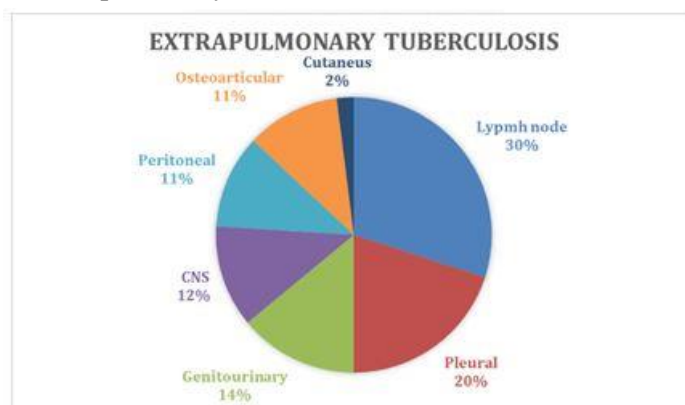


Figure 1. Different ways of extrapulmonary tuberculosis.

Peritoneal tuberculosis (TbP) encompasses 11% of the forms of extrapulmonary tuberculosis, it occurs more frequently in female patients of approximately 50 years old, of a symptomatic onset in patients with HIV. (16,17)

The diagnosis of TbP is difficult due to its nonspecific presentation and challenging since it can affect the entire gastrointestinal tract, has similarities with other abdominal conditions (complicated acute appendicitis, Crohn's disease, and malignant neoplasms), and is often accompanied by chronic conditions (liver cirrhosis and immune diseases, mainly HIV infection)

The most common symptom is weight loss, followed by abdominal pain manifesting over a period of weeks to months. Other common

symptoms are fever, ascites, abdominal distention, palpable adnexal masses and abdominal tenderness, fatigue, and general malaise; and in women: menstrual abnormalities and pelvic pain. (16, 21, 22, 23)

Tuberculosis spreads to the peritoneum in 3 ways:

1. Hematogenous or lymphatic: after reactivation of pulmonary tuberculosis or solid organs.
2. Ingestion of milk and/or secretions with bacilli: dissemination in intestinal submucosal lymphoid tissue, leading to infection of deep layers and adjacent lymph nodes to finally reach the peritoneum.
3. Direct spread from an adjacent infected focus: for example, a Fallopian tube or psoas abscess. (Figure 2).

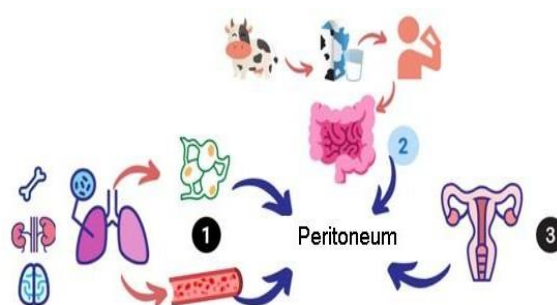


Figure2. Different ways of extrapulmonary tuberculosis

There are 3 Variants of Peritoneal Tuberculosis:

- Ascitic-humid: characterized by large amounts of exudate.
- Fibrous-fixed: characterized by intestinal adhesions along the omentum and mesentery.
- Dry: characterized by abrupt inflammation with diffuse fibrous adhesions and peritoneal nodules. (The 3 variants can be presented in combination).

There are several laboratory diagnostic tests for peritoneal tuberculosis, however, none by itself is standardized, as it is not sufficiently specific or sensitive (22,16)

The tests that constitute the “gold standard” for diagnosing tuberculous peritonitis are the peritoneal biopsy obtained by laparotomy or laparoscopy. Laparotomy and laparoscopy make it possible to distinguish between these variants and have a sensitivity of upto100%. (16, 20,23)

Confirmatory Tests Include:

Evidence of tuberculoid (caseous) granuloma observed on his to pathological analysis.

- Acid fast bacilli stained with Ziehl-Neelsen with sensitivity up to97%.
- Culturewithsensitivitybetween21-23%.
- White blood cell count of 500-1500 cells /mm³ (lymphocyte predominance) depending on the patient's immune status (except for patients with renal failure in whom neutrophils predominate).
- The Polymerase Chain Reaction Test (PCR), which is limited by its high incidence of false positives.(16, 20)

In Addition, it Should be Considered:

- In tuberculous peritonitis, the peritoneal fluid shows a serum

albumin / ascites (GASA) gradient <1.1g/dl (this is obtained by subtracting serum albumin minus album in from the sample and allows differentiating ascites secondary to liver disease such as portal hypertension, from non-liver diseases) and proteins> 2.5mg/dl.

- Levels ≥ 30 U / L of Adenosine deaminase (ADA) have shown diagnostic utility with sensitivities and specificities of up to 90% (except in those with cirrhosis for having lower than normal levels).
- The CA125 antigen (it is a sensitive but non specific tumor marker for ovarian carcinoma) can be raised to approximately 10 times the normal value in patients with peritoneal tuberculosis. At limits of 35 U / ml,it has a mean sensitivity of83.33%and a specificity of 50%.
- Routine hematological tests are nonspecific since the results are usually within normal parameters, on the other hand, the sensitivity of immune tests is reduced in patients with peritoneal tuberculosis who are immuno compromised(16,21,22).

Complementary studies: Imaging techniques such as ultrasound and computed tomography can be used initially to reveal common abdominal changes in TbP, such as ascites (freeorloculated), lymphadenopathy, peritoneal thickening and nodules, adhesions and fibrinous septa; they also facilitate peritoneal needle biopsy or ascites fluid aspiration. Computed tomography plus18F fluoro deoxy glucose positron emissiontomography increases sensitivity by determining peritoneal thickening of unknown origin. (21,16)

4. ACUTE ABDOMEN IN THE PATIENT WITH HIV

Acute abdomen is a complex disease that includes various syndromes and is responsible for upto 10% of visits to the emergency services, as well as most admissions and surgical interventions (24).

It has 4 Main Characteristics:

- 1) Damage to the peritoneum, prevailing the symptom of abdominal pain.
- 2) Its systemic and intra-abdominal pathophysiology rapidly evolves into serious stages, which carry a potential risk of mortality.
- 3) It requires timely diagnosis and treatment to achieve optimal resolution.
- 4) Its treatment is usually surgical.

In Turn, the Etiopathogenesis of Peritoneal Injury Comprises Two Mechanisms:

- Initial direct involvement of the peritoneum, diffuse or localized, septic, or aseptic, traumatic or non-traumatic.
- Initial damage to the viscera of the digestive tract, mainly intestinal obstructive causes, with secondary peritoneal involvement.

According to the mechanisms mentioned, peritonitis can be divided into primary, secondary, or tertiary:

- Primary peritonitis has a lower incidence and is acquired by distant infectious foci through the hematogenous or lymphatic route.
- Secondary peritonitis occurs directly from an abdominal inflammatory focus, perforation of the hollow organs, pouring septic content into the peritoneal lumen. It can be due to septic (appendicitis, diverticulitis) or aseptic (pancreatitis) spread.
- There is a third type of peritonitis, which corresponds to those cases in which an infection occurs secondary to the failure of previous treatment (24).

Normally, the acute abdomen usually manifests with abdominal pain, abdominal muscle contracture, abdominal distention, and reflex vomiting, giving rise to multiple differential diagnoses, especially in the patient with HIV where we increase the number of clinical variables, such as opportunistic infections, neoplasms and other types of diseases. inflammatory.(24,25)

In patients with HIV, acute appendicitis prevails as the first cause of acute abdomen (3.6%), being 36 times higher than in the population without HIV. Other etiologies reported in the literature are acute cholecystitis, intestinal perforation, obstruction, abscesses, and lymphomas. In patients with HIV, it is vitally important to rule out intra-abdominal spread of *Mycobacterium tuberculosis*, since, although it is not always considered one of the main etiologies of acute abdomen, there are studies such as the one carried out in Peru by Montoya et al. (26) where intra-abdominal tuberculosis is the main cause of acute abdomen (25,26).

5. CASE REPORT

A 31-year-old male patient with a family history of type 2 diabetes mellitus and arterial hypertension; previous hospitalization for left ankle fracture; blood transfusion 3 years ago and recent diagnoses of HIV infection, colitis and gastritis.

He presented to the emergency department due to severe abdominal pain, 2-month-old diarrhea, and nocturnal sweating. It refers to an assessment by the surgery service with the following vital signs: BP 121/81 mmHg, HR 109 bpm BR 24 bpm Temperature 36.5 °C.

On physical examination, he was dehydrated with symptoms of acute appendicitis; abdominal radiography without conclusive findings;

abdominal USG reports free fluid in the right iliac fossa without identification of the appendix; abdominal CT refers to the presence of collection and mesenteric fat striation in the right iliac fossa, for which reason surgical intervention was decided by exploratory laparotomy in which turbid peritoneal fluid was found, a necrotic appendix in a retroileal situation with perforation in the middle third, as intraoperative findings were reported : leaking appendicular stump, with

predominantly ileocolonic mesentery lymph node thickening of upto 1 cm and adhesions of the ascending mesocolon towards the duodenum and cobble stone lesions in the ileum and peritoneum of undetermined origin (image 1).

Therefore, an appendectomy, drainage placement, right hemicolectomy, ileostomy, primary closure of the duodenum, and cavity lavage were performed.

Given the surgical findings, the diagnosis of suspected peritoneal and intestinal tuberculosis secondary to immunodeficiency is established, which is later confirmed with complementary

studies.

The patient is kept under surveillance and post operative care for 30 days.

Patient is maintained with total parenteral nutrition for 14 days. On the 19th day of hospital stay, management with trimethoprim /sulfamethoxazole was started due to CD4 and viral load (CD4 22 cel/ μ L, viral load 1,158,561); antifymic management was started after an internal medicine and infectious disease assessment. It is not possible to start antiretroviral management due to suspected tuberculosis and duodenal fistula, it requires third-level medical care management.

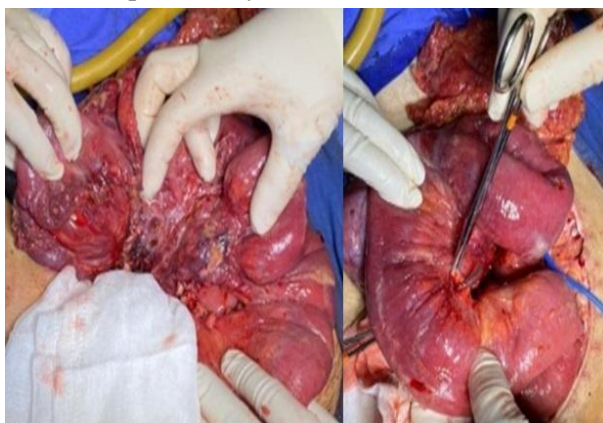


Image 1. Cobblestone lesions

6. CONCLUSION

The acute abdomen in the patient with HIV implies a challenge in the diagnosis due to an increase in probable etiologies that can generate it. The predominance of opportunistic infections and those with atypical dissemination, such as the case of intra-abdominal tuberculosis is presented in this article, becomes important.

In Mexico, Tb is endemic and there is a high incidence of HIV, however, cases of intra-abdominal Tb are not usually diagnosed until late stages or by incidental surgical findings.

The age of presentation of TbP is usually during the sixth decade of life, thus making its timely diagnosis difficult due to the increase in exacerbated pathologies at that age.

Based on the above, a close follow-up of patients with a diagnosis of HIV can reduce the development of complications that require invasive procedures.

REFERENCES

- [1] Piñera C, Blamey R, Villena R. Vacunas en pacientes con VIH/ SIDA. [REV.MED. CLIN. CONDES - 2020; 31(3-4) 317-329. <https://doi.org/10.1016/j.rmcl.2020.04.001>
- [2] Galvani CP, Casale AH, Mani fest acciones neurológicas del infoma sistémico en pacientes con VIH/SIDA. NEUROL ARG.2020; 12 (1): 13-19. doi:<https://doi.org/10.1016/j.neuarg.2019.10.001>
- [3] Ceballos S, Carbajal G, Arellanos Y, Ramírez G, González A, Martínez A. Informe Histórico VIH- SIDA 2do Trimestre 2020. Sistema de Vigilancia Epidemiológica de VIH. Secretariade Salud. 2020
- [4] Gutiérrez F. Infección por el VIH/sida: ¿El principio o el fin de la primera gran pandemia contemporánea?. Rev Clin Esp.2017; (217) 468-472 doi:<http://dx.doi.org/10.1016/j.rce.2017.04.004>
- [5] Torruco U. Infección por VIH y sida, dos mundos que se apartan. Revista de la Facultad de Medicina de la UNAM. Vol.59, N.o1. Enero-Febrero 2016
- [6] Lopera MM, Lemos Y. Factor asociado

- económico osclínicos asociados con infección oportunista en pacientes con HIV a través del sistema de salud. *Biomédica* 2019;39:186-204. doi: <https://doi.org/10.7705/biomedica.v39i2.4508>
- [7] CENSIDA. Guía de manejo antirretroviral de las personas con VIH. Secretaría de Salud. 2019. Decima edición. México.
- [8] Furin J, Cox H, Pai M. Tuberculosis. *The Lancet*; London Tomo 393, N.º 10181, (Apr 20, 2019): 1642-1656. doi: [http://dx.doi.org/10.1016/S0140-6736\(19\)30308-3](http://dx.doi.org/10.1016/S0140-6736(19)30308-3)
- [9] Orozco-Andrade I, Acosta-Loya JA, Bravo-Rodríguez G, Martínez-Lozano FN, Enríquez-Porras A, Espinoza Hernández ME, et al. Epidemiología de tuberculosis pulmonar en población mi ante. *Neumol Cir Torax*, 2018, Vol. 77, No. 2: 125-131
- [10] Dheda K, Barry CE 3rd, Maartens G. Tuberculosis. *Lancet*. 2016;387:1211-26. doi: [http://dx.doi.org/10.1016/S0140-6736\(15\)00151-8](http://dx.doi.org/10.1016/S0140-6736(15)00151-8)
- [11] Vázquez JG, Acosta C, Miranda MG, Fuentes Y, Labra MG, Pacheco DO, et al. Análisis de una serie de casos de tuberculosis en pacientes pediátricos atendidos en un hospital de tercer nivel. *Bol Med Hosp Infant Mex*. 2017;74(1):2733. doi: <http://dx.doi.org/10.1016/j.bmhmx.2016.10.008>
- [12] Ramírez-Lapausa M, Menéndez-Saldaña A, Noguerado-Asensio A. Tuberculosis extrapulmonar, una revisión. *Rev Esp Sanid Penit* 2015;17:3-11
- [13] Chaves W, Buitrago J, Dueñas A, Bejarano J. Acerca de la Tuberculosis Extrapulmonar. *Reprt Med Cir*. 2017;26(2):90-7
- [14] Global tuberculosis report 2019. Geneva: World Health Organization; 2019. Licence: CCBY-NC-SA 3.0 IGO.
- [15] Luque L, Rodrigo T, García-García JM, Casals M, Millet JP, Cayla J, et al. Factors Associated With Extrapulmonary Tuberculosis in Spain and Its Distribution in Immigrant Population. *Open Respir Arch*. 2020; 2(3):119-126 doi: <https://doi.org/10.1016/j.opresp.2020.04.004>
- [16] Wu DC, Averbukh LD, Wu GY. Diagnostic strategies for peritoneal tuberculosis: A review. *J Clin Transl Hepatol* 2019;7(2):140-148. doi: 10.14218/JCTH.2018.00062.
- [17] Gómez-Piña JJ. Tuberculosis peritoneal. *Med Int Méx*. 2018 mayo-junio;34(3):490-496.
- [18] Mehta P, Raj A, Singh N, Khuller G. Diagnosis of extrapulmonary Tuberculosis by PCR. *FEMS Immunol Med Microbiol* 2012;66:20-36
- [19] Castro J, López A, Villegas J, Vilchis M. Tuberculosis genitourinaria. *Rev Mex Urol* 2011;71(1):18-21
- [20] Carrascosa MF, Salcines-Caviedes JR, Corral-Mones JM, Gómez-Román J, Cano-Hoz M (2014) Intestinal Tuberculosis as First Manifestation of Human Immunodeficiency Virus (HIV) Infection. A Single History Snapshot. *J Mycobac Dis* 4:141. doi: 10.4172/2161-1068.1000141
- [21] Ruiz J, Ganji M, Canha C, Isache C. A Challenging Diagnosis of Ascites: A Case Report of Peritoneal Tuberculosis. *Hindawi. Case Reports in Infectious Diseases*. Volumen 2018, Artículo 8136476, 3. doi: <https://doi.org/10.1155/2018/8136476>.
- [22] Bulut D, Katipoglu B, Basara E, Ates I, Yilmaz N. A Case Report of Peritoneal Tuberculosis: A Challenging Diagnosis. *Hindawi. Case Reports in Infectious Diseases* Volumen 2018, Artículo 4970836, 3 p. doi: <https://doi.org/10.1155/2018/4970836>.
- [23] Vasen W, Mauriño E, Ferro D, Brotto C, Fernández P, Cabanne A. Síndrome de tuberculosis abdominal. Análisis de 100 casos clínicos. *Acta Gastroenterológica Latinoamericana*. 2016;46:205-212.
- [24] Mayo M, Pacheco J, Vázquez J. Abdomen Agudo. *Medicine*. 2016;12(7):363-79
- [25] Moran G, Muñoz W, Orrala J. Incidencia de abdomen agudo quirúrgico en pacientes infectados con virus de inmunodeficiencia humana en el hospital Abel Gilbert Pontón de enero a diciembre de 2015. *Espirales*. 2018. ISSN: 2550-6862
- [26] Montoya L, Rodríguez E, Zúñiga G, Yamamoto G, González E. Abdomen agudo en pacientes con VIH/SIDA atendidos en un hospital nacional de Lima, Perú. *Rev Peru Med Exp Salud Pública*. 2014;31(3):515-19.

Citation: Flores-Almanza José et al. "Acute Abdomen in a Patient with HIV, a Challenge for the Surgeon. Systematic Review and Case Report of Intra-Abdominal Tuberculosis". *ARC Journal of Surgery*. 2022; 8(1):1-6. DOI: <https://doi.org/10.20431/2455-572X.0801001>.

Copyright: © 2022 Authors. This is an open-access article distributed under the terms of the Creative Commons Attribution License, which permits unrestricted use, distribution, and reproduction in any medium, provided the original author and source are credited.