



Terminal Ileal Necrosis with Mesentery Avulsion Secondary to Meckel Mesodiverticular Band. Case Report

Del Carmen Ortega Ignacio MD¹, Sanchez Dauth Dulce Maria MD², Gonzalez Villegas Hedler Olaf MD³, Gonzalez Valdez Luis Alberto MD⁴, Rodriguez Bautista Julio Orlando MD⁵, Serrano Ramos Javier Enrique MD⁶, Monroy Cedillo Jose Lius MD¹, Marcos Irving Salazar Jimenez MD^{1*}

¹Hospital Central Norte de Petroleos Mexicanos

²Hospital Christus Muguerza del Parque

³UMAE IMSS Leó Guanajuato

⁴Hospital General Dr. Ruben Leñero

⁵Hospital Regional de Petróleos Mexicanos Salamanca, Guanajuato

***Corresponding Author:** Marcos Irving Salazar Jimenez, Hospital Central Norte de Petroleos Mexicanos, Mexico. E-mail: buismedina_5@hotmail.com

Abstract

Background: The Meckel's diverticulum is the most frequent congenital anomaly of the gastrointestinal tract. The mesodiverticular band is an embryological remnant of the vitelline circulation, when it cannot be obliterated, it can cause complications such as intestinal obstruction, among others.

Material And Methods: Male of 58 years-old, comes to the emergency room by a clinical picture of intestinal occlusion, with an internal hernia in the CT scan. For this diagnosis, an exploratory laparotomy is performed finding the presence of a Meckel's diverticulum conditioning terminal ileal necrosis.

Conclusion: The present case is a rare entity, especially in the adulthood, but the Meckel's diverticulum is manifested by complications that almost always require emergency surgical intervention.

Keywords: Meckel's Diverticulum, Ileal necrosis, Intestinal obstruction, Mesodiverticular band.

1. BACKGROUND

The Meckel's diverticulum is the most frequent congenital anomaly of the gastrointestinal tract. It appears secondary to the incomplete occlusion of the omphalomesenteric duct, that normally happens between the 7th and 8th week of gestation¹, it is a real diverticulum of the small bowel, containing mucosa, submucosa and muscularis propria².

In the worldwide literature this disease is associated with a rule called the "rule of the 2", because it is presented in the 2% of population, with 2 inches of length, at 2 inches from the ileocecal valve, usually is presented before two years of age and contains 2 different ectopic tissues (pancreatic and gastric are the most frequent, with the first in near 80% of the cases). It occurs at the same frequency in both sexes, but the complications are more frequent in males³. Secondary to the classic presentation in the pediatric age is unusual to consider this diagnosis

in the adulthood, in which it is silent or with unspecific clinical courses mimicking other intraabdominal diseases, making this a diagnostic challenge^{2,4}.

The three clinical images associated with Meckel's diverticulum are inflammation, low gut bleeding or intestinal obstruction. There are many mechanisms that can precipitate the intestinal obstruction, like the volvulus of small bowel around a fibrous band that is connecting the diverticulum to the umbilicus, the intestinal invagination, and the Littre hernia⁵.

2. CASE REPORT

Male of 58 years-old, without chronic diseases or surgical background, comes to emergency room for abdominal pain located in the hypogastrium with an intensity of 6/10 in the visual analog scale, accompanied with anorexia, and adynamia. He denied having nausea, vomiting or fever, with the last evacuation 2 days previous to consultation. Is evaluated and discharged with

prokinetic management, but the abdominal pain increase and returns 6 hours later, is evaluated and hospitalized for study.

A physical exam with Glasgow of 15 points, with abdominal distention, at palpation with a soft abdomen, painful at media and deep palpation in lower hemiabdomen, with tympanic sound in upper hemiabdomen. In his lab test he presented leukocytosis $17.8 \times 10^3/\text{ml}$, neutrophils $15.6 \times 10^3/\text{ml}$ (87.4%), hemoglobin 19.6 gr/dl, hematocrit 59.1%, platelets $300 \times 10^3/\text{ml}$, creatinine 1.52 mg/dl and lactate 5.8mmol/l.

In the plain abdomen x-rays in two projections, we observed dilation of small bowel loops, the abdominal ultrasound with abundant liquid in small intestinal loops and diameter of 3.1 cm, interloop free liquid in the subdiaphragmatic right space and subhepatic space. In the CT scan, we observe a small bowel obstruction with a central transition zone in the mesogastrium, probably secondary to an internal hernia (Fig. 1), the free liquid in the peritoneal space (Fig. 2). After the location of the nasogastric tube, it drained 2000 ml of fecaloid aspect liquid. According to clinical and CT scan findings, an exploratory laparotomy is performed.

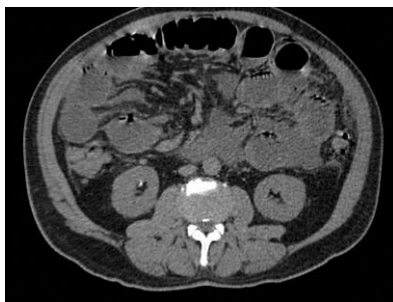


Figure1. Simple abdominal CT scan, with evidence of small bowel obstruction and a central transition zone in mesogastrium, probably secondary to an internal hernia or adhesions.

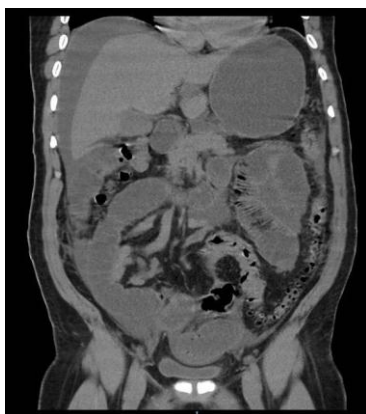

Figure 2. The free liquid in superior and inferior peritoneal recesses (1 to 8 UH).

Surgical findings include small bowel loops dilated, with a Meckel's diverticulum at 50cm of the ileocecal valve (Fig. 3) (Fig. 4). We observed a flange to the terminal ileum producing twisting and avulsion of the mesentery, with ileal necrosis of about 150cm (Fig. 5); an intestinal resection of the affected segment is completed at 40cm from the ileocecal valve and 140cm from the Treitz angle, with ileal-ileal anastomosis in a lateral-lateral fashion with stapler, and incidental appendectomy is completed too and an open drain placed to the pelvic hollow.

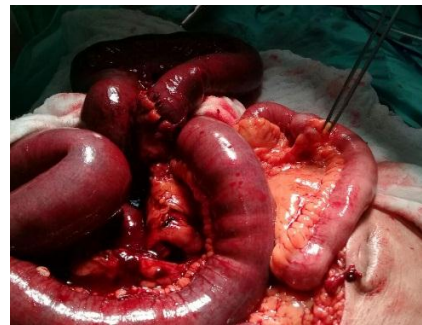

Figure3. Meckel diverticulum located at 50 cm from the ileocecal valve with flange towards the ileum.

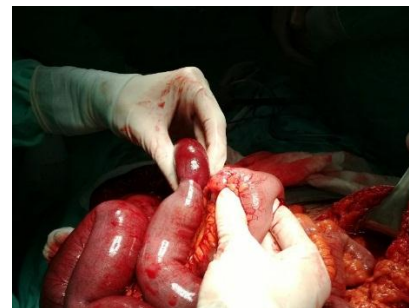


Figure 4. Mesenteric avulsion secondary to Meckel's mesodiverticular band in the ileum.

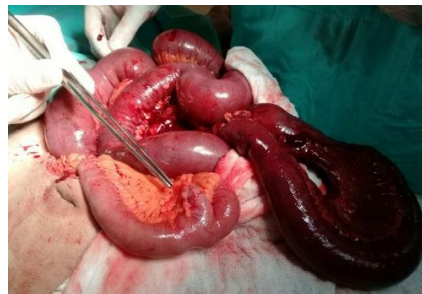

Figure5. Necrosis of 150cm of the ileum.

Post-surgical management includes fasting for three days, antibiotic and analgesic medication. The nasogastric tube was withdrawn on the third day, with an introduction with a liquid diet and the next day soft diet, with discharge at fourth day after surgery without complications, and posterior follow up in the external consult, where the pathologic report confirm the diagnosis (Fig. 6).

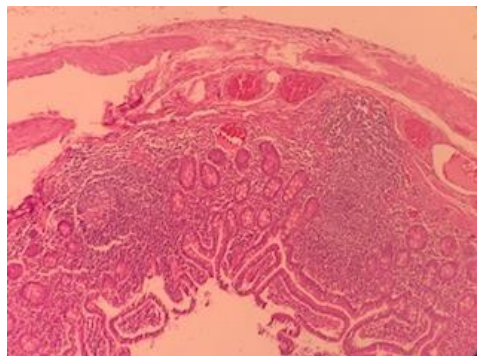


Figure 6. Hematoxylin and eosin 20x sample showing the diverticulum with the three hats of the abdominal wall, weakening of the Wall and inflammatory infiltrate. Normal intestinal mucose membrane from the ileum.

3. DISCUSSION

Initially, the Meckel's diverticulum was described by Fabricius Hildanus in 1598, posteriorly in 1809 by Johann Friedrich Meckel, who described extensively the anatomy and embryology, and for this reasons, this pathology receives their eponymous⁶.

The mesodiverticular band is an embryologic remnant of the vitelline circulation that brings the arterial blood to the Meckel's diverticulum. In the case of an absence of involution, an arterial band persists and it extends from the mesentery to the vertex of the antimesenteric border of the diverticulum, creating an opening across which the intestinal loops can herniate and produce an intestinal obstruction. This kind of internal hernia is a very rare cause of small bowel obstruction^{6,7}.

In adults, the most frequent location of the Meckel's diverticulum is the antimesenteric border of the ileum, at E 60-100 cm from the ileocecal valve, different than the location in the child (30-60 cm)⁶.

In the list of intestinal obstruction, the congenital anomalies like the presence of a mesodiverticular band represent less than 1% of the cases⁸.

The integral diagnosis, with the abdominal CT scan as the gold standard for evaluation, with a sensibility of 90-95% and specificity of 96% for the diagnosis of small bowel obstruction, and that in 95% of cases it locates the exact site of obstruction and the etiology, in addition to indirect signs of intestinal hypoperfusion.^{9,10,11}

About the surgical treatment, the surgical resection with diverticulectomy or segmental resection of ileum with anastomosis is the best option of treatment. In our case, the segmentary resection was performed by the ischemic necrosis

of the intestinal segment affected with ileal-ileal anastomosis. The laparoscopic surgical management depends on the surgeon abilities and the hospital resources but seems an excellent option in this cases.¹²

4. CONCLUSION

The Meckel's diverticulum is a low-frequency gastrointestinal tract pathology, however, the clinical presentation is characterized by the associated complications. There is no need for a specialized test when the clinical suspicious is present and the surgical management must not be delayed. The incidental appendectomy is indicated in all the cases.

REFERENCES

- [1] Paras K. Pandove, Ashish Moudgil, Megha Pandove, Chandrashekhar, Divya Sharda, Vijay K. Sharda. Meckel's diverticulum mesentery along with its band forming a hernial sac: A rare case of internal herniation. *International Journal of Surgery Case Reports* 10 (2015) 17–19.
- [2] Mazin Al Janabi, Madan Samuel, Andrea Kahlenberg, Sujith Kumar and Mina Al-Janabi. Symptomatic pediatric Meckel's diverticulum: stratified diagnostic indicators and accuracy of Meckel's scan. *Nuclear Medicine Communications* 2014, 35:1162–1166.
- [3] Andrew A.H. Hadeed, Robert R.A. Azar, Nabil N.A. Azar, Brion Benninger. Meckel's diverticulum complicated by axial torsion and gangrene. *Journal of Surgical Case Reports*, 2015; 3, 1–3.
- [4] Aziz Sumer, Ozgur Kemik, Aydemir Olmez, A. Cumhur Dulger, Ismail Hasirci, Umit Ilklerden, Et. Al. Small Bowel Obstruction due to Mesodiverticular Band of Meckel's Diverticulum: A Case Report. *Case Reports in Medicine* . 2010. Volume 2010, 1-3.
- [5] Y. Narjis, H. Halfadl, A. Agourram, K. Rabbani, B. Finech. A Rare Internal Herniation in Adult: Meckel's Diverticulum. *Indian J Surg* (2014) 76(1):5–7.
- [6] C.R. López-Lizárraga, M.P. Sánchez-Muñoz, G.E. Juárez-López, L. Pelayo-Orozco, L.F. De la Cerda-Trujillo, C.F. Ploneda-Valencia. A rare case of a strangulated Littre's hernia with Meckel's diverticulum. *International Journal of Surgery Case Reports* 33 (2017) 58-61.
- [7] Mirko Bertozzi, MD, PhD, Bernardino Melissa, MD, Elisa Magrini, MD, Giuseppe Di Cara, MD, Ph.D., Susanna Esposito, MD, Antonino Apignani, MD, Ph.D. Obstructive internal hernia caused by mesodiverticular bands in children. *Medicine* (2017) 96:46.
- [8] Gustavo Capelão, Miguel Santos, Sandra Hilário, Mónica Laureano, João Nobre, Inês

- Gonçalves. Intestinal Obstruction by Giant Meckel's Diverticulum. *GE Port J Gastroenterol* 2017; 24: 183–187.
- [6] Alexandra Platon, Pascal Gervaz, Christoph D. Becker, Philippe Morel, Pierre-Alexandre Poletti. Computed tomography of complicated Meckel's diverticulum in adults: a pictorial review. *Insights Imaging* (2010) 1:53–61.
- [7] Jae Min Lee, Chan Dong Jeon, Seung Han Kim, Jong Soo Lee, Seung Joo Nam, Hyuk Soon Choi, Et. al. Meckel's diverticulum detected by computed tomographic enterography: Report of 3 cases and review of the literature. *Turk J Gastroenterol* 2014; 25: 212-5
- [8] V K Kotha, MD, A Khandelwal, MD, S S Saboo, MD, Frcr, A K P Shanbhogue, MD, V Virmani, MD, Frcr, E C Marginean, MD, Et. al. Radiologist's perspective for the Meckel's diverticulum and its complications. *Br J Radiol* 2014;87:1
- [9] Chee S. Wong, Leanne Dupley, Haren N. Varia, Darek Golka, Thu Linn. Meckel's diverticulitis: a rare entity of Meckel's diverticulum. *Journal of Surgical Case Reports*, 2017;1, 1–3.

Citation: *Del Carmen Ortega Ignacio et al. Terminal Ileal Necrosis with Mesentery Avulsion Secondary to Meckel Mesodiverticular Band. Case Report. ARC Journal of Surgery.2018;4(3):1-4.doi:dx.doi.org/ 10.20431/2455-572X.0403001.*

Copyright: © 2018 Authors. This is an open-access article distributed under the terms of the Creative Commons Attribution License, which permits unrestricted use, distribution, and reproduction in any medium, provided the original author and source are credited.