

Psychiatric Manifestation in Setting of Arachnoid Cyst: A Case Series

Kamal Patel MD^{1*}, Ajayi Oluwadamilare MD¹, Kelly Melvin MD¹, Cornelius Thomas MD²

¹Department of Psychiatry and Behavioral Medicine, Marshall University, Joan C. Edwards School of Medicine, Huntington, WV 25701, USA

²Hershel Woody Williams VA Medical Center, 1540 Spring Valley, Drive Huntington, WV 25704, USA

***Corresponding Author:** Kamal Patel MD, Department of Psychiatry and Behavioral Medicine, Marshall University, Joan C. Edwards School of Medicine, Huntington, WV 25701, USA, Email: patelk@live.marshall.edu

Abstract: Arachnoid cysts are benign space occupying lesions containing cerebrospinal fluid which are usually diagnosed incidentally on neuroimaging due to most cases being asymptomatic. They are scarce case in the literature shown coexistence of psychiatric illness and arachnoid cyst, however this clinical presentation varies depending on the size and location of the arachnoid cyst. Here we present three cases of various psychiatric symptomatology in setting on arachnoid cyst. Although we cannot conclude the etiology of our patient's illness solely from the arachnoid cyst, we do believe it may have played some role in the patient's symptomology as shown by prior case reports in the literature.

Keywords: Arachnoid cyst, anxiety, depression, bipolar disorder, traumatic brain injury, neuropsychiatry

1. INTRODUCTION

Arachnoid cysts (AC) are benign lesions containing cerebrospinal fluid which account for 1% of all intracranial space occupying lesions [1] found anywhere in central nervous system. Most ACs are usually diagnosed incidentally on neuroimaging as most are asymptomatic with 50% percent of the cysts found in the Sylvian fissure [2]. Symptoms are often led by cyst pressurizing the surrounding brain tissue, cranial nerves, and or leptomeninges [3]. The most common neurological complain is headache [1] along with other symptoms which include ataxia, visual disturbance, dizziness, and impaired memory [4]. Per literature review, there are several reports of arachnoid cysts co-existing with psychiatric illnesses with varying presentations depending on location and size of cyst; with some of the cysts being the sole abnormality.

Here, we present a case of a 51-year-old male with bipolar affective disorder diagnosed with new onset psychosis alongside an established right sided arachnoid cyst, and two cases of 68 and 56-year-old male respectively with depression and anxiety in presence of left sided arachnoid cyst

2. CASE STUDY

2.1. Case 1

The patient is a 51-year-old Caucasian male

with a medical history of coronary artery disease status post coronary artery bypass grafting, hypertension, hyperlipidemia, migraine headache and an established 4 x 4.3 x 2.9 cm arachnoid cyst located in the right middle cranial fossa with evidence of temporal lobe displacement as shown in figures 1 and 2. Patient was evaluated for depression by primary care before establishing with our service. He reported long-standing undiagnosed feelings of depression since childhood due to physical and sexual abuse which occurred from 5 – 15 years of age. Additionally, he endorsed mood instability with several days of elevated mood followed by days of feeling depressed and down which had worsened in severity over time.

During his periods of elated mood, patient endorsed increased energy, irritability, activity, decreased need for sleep (1-2hrs) and hypersexuality with multiple partners. He denied periods of relative mood stability, with mood alternating over a period of 3-4 weeks. During initial visit patient was hypomanic and then went into depressed phase during the four-week interval between appointments. He was diagnosed with bipolar disorder secondary to general medical condition and pharmacotherapy initiated with oxcarbazepine to which quetiapine was added during subsequent appointments due to patient endorsing new onset non-commanding auditory hallucination as well as paranoia.

Oxcarbazepine was titrated to 600mg twice a day and Quetiapine was titrated to 300mg at

bedtime which resulted in improvement with mood stability and psychotic symptoms.

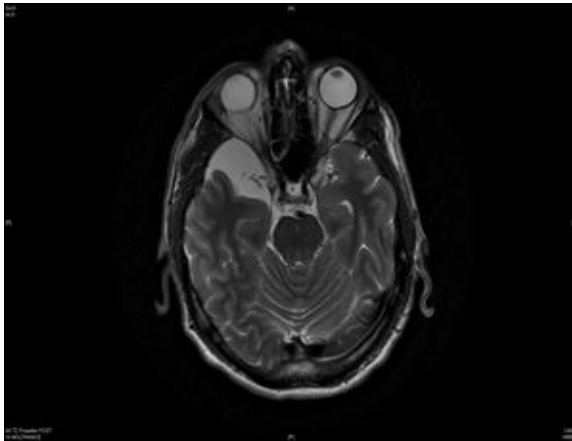


Figure 1

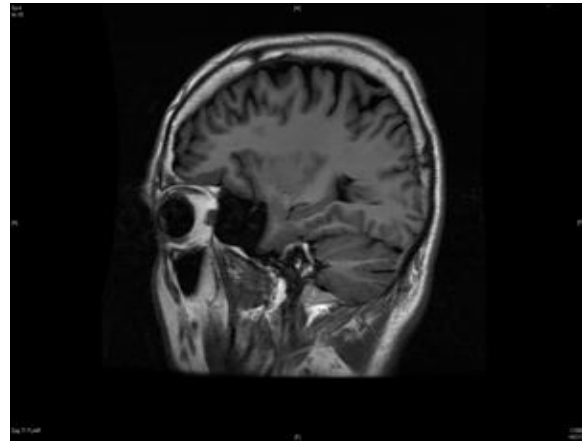


Figure 2

2.2. Case 2

68-year-old male with a long-standing history of generalized anxiety and excessive worry. He initially presented with daily anxiety and fear of rejection at the age of 20 while serving in the military. He was not able to cope with military service and discharged with a diagnosis of “neurosis”. Throughout his adult life, fear of failure and rejection caused significant social and occupational impairment, with chronic feelings of loneliness and hopelessness. The patient had no history of hypomanic or psychotic symptoms. He experienced intermittent suicidal ideation without any attempts. He had no motor weakness, sensory deficit, dizziness or memory problems, although he complained of chronic mild tremors in both hands and legs. Past medical history was unremarkable except of a history of head trauma secondary to a fall from a truck at age of 18.

The patient had been treated with various antidepressants and mood stabilizer (including

lithium) but was not able to achieve remission from symptoms. He had two courses of electroconvulsive therapy with brief periods of clinical improvement. He experienced some symptomatic relief with duloxetine 60mg daily, lorazepam 1mg three times a day and trazodone 200mg at bedtime.

On mental status exam, patient had poor eye contact, mild psychomotor slowing, reduction in facial expressions and mild bilateral kinetic hand tremor. Speech was hesitant, low volume, prosody was flat, limited variation in pitch with paucity content. Affect was flat and dysphoric. Thought process was notable for some latency to respond to questions. He had problems generating word list, but otherwise cognitive functioning was within normal limits. There were no focal motor or sensory deficits noted.

Patient MRI of head (figures 3 and 4) shows an arachnoid cyst along the left anterior temporal lobe measuring 3.5 x 5.2 cm.

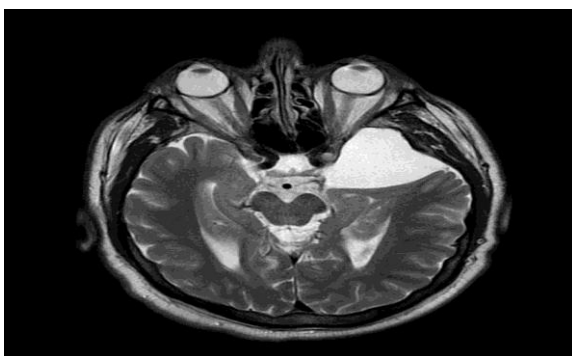

Figure 3

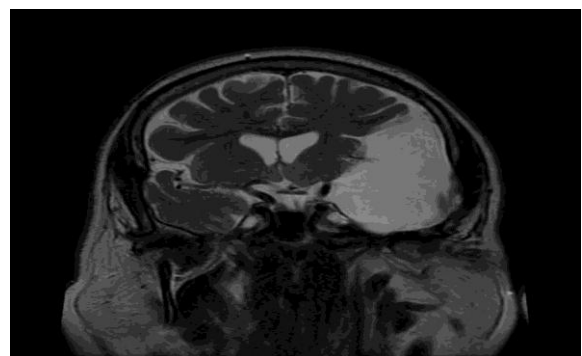


Figure 4

2.3. Case 3

56-year-old male with a long-standing history of generalized anxiety, excessive worry and dysphoric mood. Psychiatric symptoms

noticeable after head injury due to a fall when he was 26 years old. Patient reported daily severe anxiety and generalized fear with

minimally responsive to various psychotropic medications or anticonvulsants. Anxiety symptoms worse in public places or when he leaves his house. Patient reported having "spell" during which he gets dizziness, light-headed with mild disorientation; lasting several minutes. He denies any motor seizures. He complains of mild irritability, subjective short-term memory problems and chronic insomnia. Patient reported that he finds it difficult to communicate with "anyone." His relationship with his wife is stable, however he prefers to be alone. He had no motor weakness and or sensory deficit. His daughter does have special needs due to "cyst on brain and problems with speech". Patient reported some symptomatic relief with Venlafaxine XR 300mg daily,

Clonazepam 0.5mg twice a day and Gabapentin 600mg three times day.

On mental status exam, patient had poor eye contact, moderate generalized shaking of arms and legs with fidgeting and wringing of hands. Speech was monotone with normal volume and rate. Affect was guarded, anxious, apprehensive with restricted range. Thought process was logical and goal directed, no flight of ideas. Thought content was without delusions or hallucinations. Cognition functioning was grossly within normal limits.

Patient MRI of head (figures 5 and 6) showed a large left anterior temporal lobe arachnoid cyst measures 3.8 x 4.2 x 2.8 cm in size.

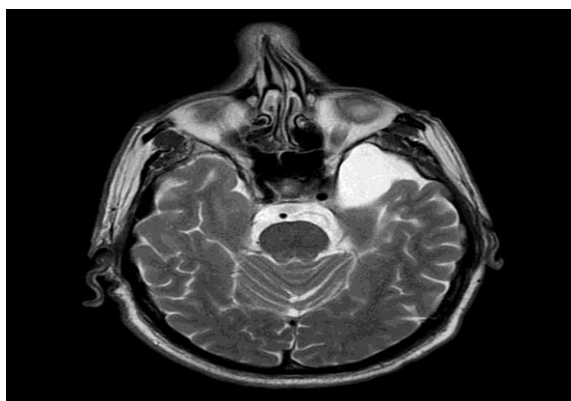

Figure 5

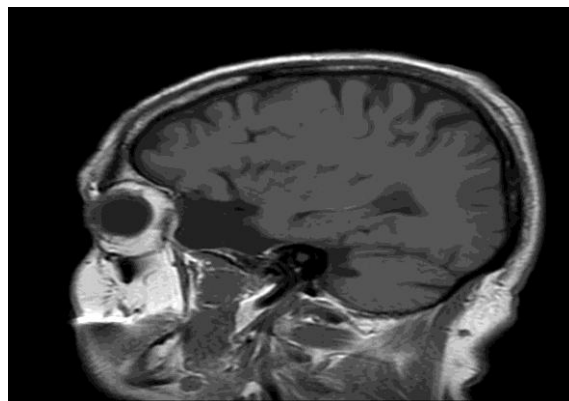


Figure 6

3. DISCUSSION

Here we present three cases of patient with psychiatric symptomology in presence of arachnoid cyst which may have played pivotal role in patient's presentation.

Several case reports are noted in the literature of ACs co-existing in individual with psychiatric conditions ranging from acute or new onset psychosis, schizoaffective disorder, to bipolar disorder, with no other identifiable neurologic or physiologic abnormality [3-8]. In majority of these cases, the ACs were localised to the left specifically involving either the left temporal or frontal lobe. ACs have been observed to localise to the left hemisphere with ratio of 2:1 compared to the right [9,10]. Notable symptoms observed in the cases include auditory hallucinations, persecutory & paranoid delusions, and pressured speech. However, signs and symptoms of major depression have been present in AC localized to left temporal lobe as described in a case by Bulbul et. al [11].

In our first case, patient was diagnosed with bipolar affective disorder secondary to general medical condition. Given the presence of an

established arachnoid cyst (AC) discovered incidentally during evaluation of syncope-like episodes and worsening of headache four years prior to psychiatric evaluation, suspicion arose as to any role the arachnoid cyst may be playing in the patient's presentation. AC was thought to be congenital in nature due to no reported history of head trauma or any neurological disorders. It was thought the cyst may have grown over time leading to pressure its surrounding brain structure which may have led or contributed to patient presentation.

In our second and third case both patients had presented with similar symptoms of depression along with severe anxiety. However, in both of this case, history of traumatic brain injury was known prior to their findings of arachnoid cyst on the MRI. There for it is likely the AC may have likely developed secondary to the head injury or may have played a role in worsening the size of the cyst which in turn may have resulted in contributing to deteriorating of patient psychiatric symptoms.

Management for these cases include pharmacotherapy and or surgical intervention.

Neurosurgical intervention is quite rare as arachnoid cysts are usually considered asymptomatic and the risks of intervention are thought to outweigh any potential benefits.

Some cases, however, have had neurosurgical intervention (cystoperitoneostomy) which have led to eventual resolution of symptoms. The patients who underwent surgical intervention included those who either did not improve despite extensive long-term pharmacotherapy or those who were found to have indications for neurosurgical intervention at onset [6, 7].

4. CONCLUSION

Our case along with the cases reviewed, have all had arachnoid cysts that were suspected to be of congenital origin and or secondary to traumatic brain injury and were thought to play a role in the development or contribute to their psychiatric illness. These cases add further to already scare literature involving ACs in setting of psychiatric illness and further studies are needed to strengthen the evidence between relationship of ACs and psychiatric manifestation.

REFERENCES

- [1] Naidich T, P, McLone D, G, Radkowski M: Intracranial Arachnoid Cysts. *Pediatric Neurosurgery*, 1985:112-122. doi.org/10.1159/000120232
- [2] Gelabert-Gonzalez M.: Intracranial arachnoid cysts. *Rev Neurol*. 2004, 39:1161-1166.
- [3] Claussen MC, Rohde J, Seifritz E, Schuepbach D: Arachnoid cyst in a patient with bipolar disorder: Just an incidental finding?. *Schweizer ArchivfürNeurologie und Psychiatrie*. 2013, 164:252-254.
- [4] Silva JD, Alves A, Talina M, Carreiro S, Guimarães J: Xavier M. Arachnoid cyst in a patient with psychosis: Case report. *Annals of General Psychiatry*. 2007;6(1), 16. 10.1186/1744-859x-6-16
- [5] Khan AH, Ahmed SE: Arachnoid Cyst and Psychosis.. *Cureus*. September 2017, 10-7759. doi:10.7759/cureus.1707
- [6] Vidrih B, Karlović D, Pašić MB: Arachnoid cyst as the cause of bipolar affective disorder: case report. *Acta ClinicaCroatica*. 2012, 51(4):655-659.
- [7] Bechter K, Wittek R, Seitz K, Antoniadis G. : Personality disorders improved after arachnoid cyst neurosurgery, then rediagnosed as 'minor' organic personality disorders. *Psychiatry Research: Neuroimaging*. 2010, 184(3):196-200. 10.1016/j.psychresns.2010.03.009
- [8] Mironov A, John S, Auerbach J, Jamaledine G. : Acute Onset of Psychosis in a Patient with a Left Temporal Lobe Arachnoid Cyst. *Case Reports in Medicine*. 2014:1-3. 10.1155/2014/204025
- [9] Wester K. Gender: Distribution and Sidedness of Middle Fossa Arachnoid Cysts. *Neurosurgery*. 1992;31(5), 10.1097/00006123-199211000-00018
- [10] Helland CA, Lund-Johansen M, Wester K. Location: sidedness, and sex distribution of intracranial arachnoid cysts in a population-based sample. *Journal of Neurosurgery*. 2010;113(5), 934-939. 10.3171/2009.11.jns.081663
- [11] Bulbul F, Demir B, Aksoy I, Alpak G, Unal A, Savas H.: Electroconvulsive Therapy in A Major Depressive Patient with Arachnoid Cyst. *The Journal of Psychiatry and Neurological Science*. 2013:392-394. 10.5350/DAJPN.2013260410

Citation: Kamal Patel, Ajayi Oluwadamilare, Kelly Melvin, Cornelius Tomas. *Psychiatric Manifestation in Setting of Arachnoid Cyst: A Case Series*. *ARC Journal of Psychiatry*. 2019; 4(2):1-4

Copyright: © 2019 Authors. This is an open-access article distributed under the terms of the Creative Commons Attribution License, which permits unrestricted use, distribution, and reproduction in any medium, provided the original author and source are credited.