

Psoriasiform Febrile Ulceronecrotic Mucha Habermann Disease: A New Clinical Presentation of a Case Report from Upper Egypt

Ayman Mahran^{1*}, Alaa Ghazally¹, Yasmin Salah¹, Marwa Ghazaly², Asmaa M Ahmed³

¹Dermatology, Venereology and Andrology Department, Faculty of Medicine, Assiut University, Assiut, Egypt

²Pediatrics Department, Faculty of Medicine, Assiut University, Assiut, Egypt

³Pathology Department, Faculty of Medicine, Assiut University, Assiut, Egypt

***Corresponding Author:** Ayman Mahran, Dermatology, Venereology and Andrology Department, Faculty of Medicine, Assiut University, Assiut, Egypt, **Email:** aymanderma@yahoo.com

Abstract: Febrile ulceronecrotic Mucha – Habermann disease (FUMHD) is an uncommon skin disease, which is characterized by necrotic papules and plaques that rapidly ulcerate. Here we present a 3-year-old boy, who was diagnosed as FUMHD in whom low dose corticosteroids was ineffective. However, combined treatment of high dose corticosteroids and intravenous immunoglobulins (IVIG) were more beneficial. To the best of our knowledge, this is the first case to be reported from Upper Egypt. Moreover, psoriasiform presentation was not previously addressed in the literature.

Keywords: Pityriasis lichenoides, Mucha Habermann disease.

1. INTRODUCTION

FUMHD is a rare life-threatening variant of pityriasis lichenoides et varioliformis acuta (PLEVA) that is characterized clinically by rapidly progressive necrotic and ulcerating skin lesions together with high fever and various systemic affections. Histological characteristics are typical of PLEVA. The exact pathogenesis of FUMHD remains unclear, with no universally effective treatment [1]. As far as we know, only one case was reported in our country (Lower Egypt) in children by Nofel et al in 2016 [2]. However, no cases were reported from Upper Egypt.

2. CASE REPORT

A 3 year-old, 16 Kilograms male child presented with a 12 days history of painful skin eruption, first developed over the trunk then rapidly progressed to involve neck, face and extremities. Past, family and medical histories were unremarkable.

The eruption was associated with high grade fever which was markedly prolonged and not responding to antipyretics (21 days). Poor general condition, marked irritability, agonizing pain, anorexia and frequent vomiting were noticed.

Skin examination revealed widespread reddish brown crusted discrete and confluent papules

and plaques surrounded by a thin rim of erythema, varying in size from few millimeters to several centimeters. Some lesions were covered by fine whitish scales which gave them a psoriasiform appearance before ulcerations began.

Lesions were most prominent over the trunk, neck, arms, forearms and thighs with fewer lesions on the face, scalp, genitalia, lower legs, hands and feet (figure 1). Oral and ocular mucous membranes were clinically free at the time of presentation.

The patient was hospitalized. Extensive laboratory investigations revealed microcytic hypochromic anaemia (7.5 mg/dl), hypoproteinemia, hypoalbuminemia and raised C-reactive protein (CRP). Also, erythrocyte sedimentation rate (ESR) was high. Blood culture revealed staph aureus, which was indicative of sepsis required starting intravenous antibiotics.

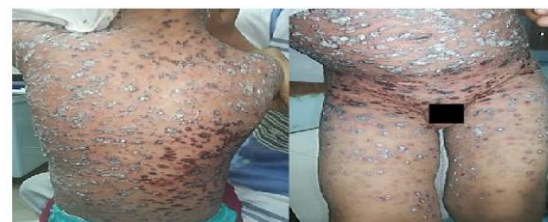

Figure1: Reddish brown crusted and psoriasiform papules and plaques disseminated over the trunk and lower extremities.

Histopathological examination revealed acanthosis of the epidermis with focal parakeratosis, crusts and neutrophilic infiltrate. In addition, basal cell vacuolar changes and focal epidermal necrosis were noted. The upper dermis showed oedema, extravasation of red blood cells and lymphocytic vasculopathy with perivascular lymphocytic infiltrate reaching the reticular dermis. Also, lymphocyte exocytosis and individual keratinocyte necrosis were seen

(figure 2). Clinicopathological correlations confirmed the diagnosis of FUMHD.

The patient received treatment in the form of acyclovir 80 mg/ kg/day, oral prednisolone (15mg/day), paracetamol (15mg/kg), along with topical application of combined steroid and antibiotic cream. However, treatment failed to stop disease progression with the development of multiple extremely painful ulcers. Also, new ulcerations appeared in the oral mucosa.

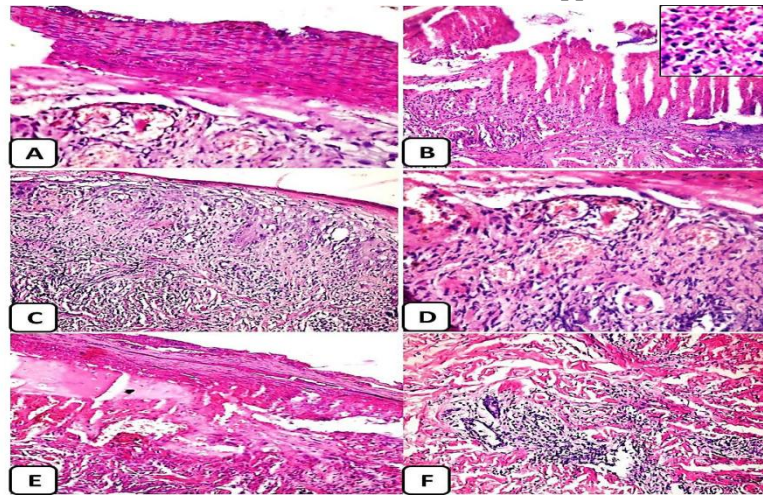


Figure2: Histopathologic examination revealed: A) Focal parakeratosis (x400), B) Ulceration of the epidermis with overlying crust (x200) and neutrophilic infiltrate (inset, x400), C) Acanthosis and basal cell vacuolar changes (x200), D) The upper dermis shows oedema, extravasation of red blood cells (x400), E) focal epidermal necrosis (x400), F) Perivascular lymphocytic infiltrate (x400).

Consequently, the dose of prednisolone was increased to 2mg/kg/day, intravenous immunoglobulin (2g/kg) over a five days cycle was added, Intravenous antibiotics (amoxicillin/clavulic acid together with azithromycin then after culture results shifted to IV vancomycin) together with meticulous daily cleaning and dressing of the ulcers. This regimen was followed by a considerable improvement in the general condition. Also, healing started and most of the crusts disappeared leaving depressed scars (figure 3)

3. DISCUSSION

Pityriasis lichenoides (PL) is a benign lymphoproliferative disorder that is regularly classified as two fundamental variants which are pityriasis lichenoides et varioliformis acuta and pityriasis lichenoides chronica (PLC). These two presentations represent a disease spectrum rather than distinct diseases, with PLEVA being more acute in onset, though some patients may show features of both [3, 4]. PL is a rare disease and its incidence is about 1/2000 people per year [5]. The mean age of onset of PL is 6.5 years, with a slight male predominance [6]. This is in accordance to our case in terms of age and sex incidence.

PLEVA is characterized clinically by rapid development of itchy and painful papulovesicles with necrotic, ulcerative, or haemorrhagic changes [7]. The condition may be confused with varicella and Kaposi varicelliform eruption. That's why our patient was put on Acyclovir. However, the course of PLEVA is significantly more prolonged [7].

Febrile ulceronecrotic Mucha-Habermann disease (FUMHD) is a rare presentation of

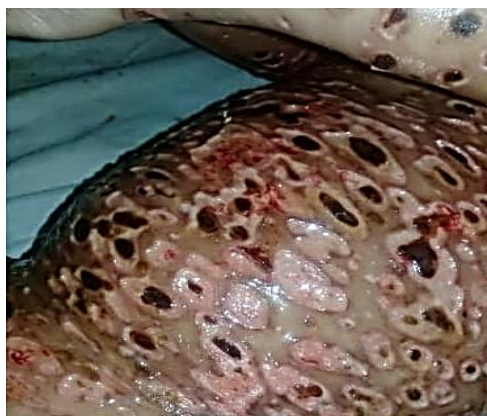

Figure3: Improved skin condition with depressed scarring.

PLEVA that may follow a diagnosis of PLEVA or occur de novo [8, 9]. No clear triggers have been distinguished for FUHMD, in spite of the fact that isolated cases have shown serologically positive to VZV and HSV-2 [10, 11]. Children and young adults are more vulnerable. In contrast to adults, children may take a shorter duration to transform from PLEVA to FUMHD with more common mucosal involvement and a more favourable prognosis [12], although deaths have been reported [2]. Affected patients show a rapid onset of necrotic papules coalescing into large ulcerations with histologic features of PLEVA [13]. Mucous membranes involvement occur in about 28% of cases (including oral, genital, and conjunctival mucosae), with systemic involvement in 45 % [7]. Systemic symptoms include high grade fever, abdominal pain, diarrhea, joint swelling, respiratory tract affection, neurological involvement, and sepsis [1, 2, and 14]. The previously mentioned manifestations were fulfilled in our case, except for diarrhea, pulmonary, central nervous system affections. However, our case showed abnormal persistence of fever despite of the appropriate therapeutic measures. In addition, early psoriasiform presentation was noted in our case. Laboratory abnormalities may include increased white blood cells count, elevated ESR and CRP, lowered hemoglobin level, mild hypergammaglobulinemia, hypoproteinemia, hypoalbuminemia, hypocalcaemia, and positive skin and blood cultures [1]. Our case showed quite similar laboratory changes with leucocytosis, anemia, raised CRP and ESR, decreased total protein and albumin levels with positive blood culture.

Nofel et.al (2016), proposed essential constant features for diagnosis of FUMHD, which are fever, acute onset of generalized ulcerative and necrotic papules and plaques, rapid progression with no evidence of spontaneous resolution and typical histopathological features of PLEVA. All of these criteria were justified in our case. However, we can add early psoriasiform presentation as another criterion.

Differential diagnoses in our case revolves around varicella, Kaposi varicelliform eruption, papulovesicular pityriasis rosea, leukocytoclastic vasculitis, lymphomatoid papulosis [1, 14] and Stevens-Johnson syndrome (SJS) [13]. However, clinicopathological

correlations were solid enough to exclude the previously mentioned differential diagnoses and confirm the diagnosis of FUMHD.

Treatment choices include prednisone, methotrexate [8, 13, 15, and 16], TNF-alpha inhibitors [17, 13] cyclosporine [2], intravenous immunoglobulins (IVIG), and extracorporeal photopheresis [18]. In our case, combination treatment of high dose corticosteroids with IVIG was of considerable benefit.

Our new remarks about FUMHD from the findings of our case, which is the first to be reported from Upper Egypt, are: Psoriasiform lesions can be an early presentation which may be indicative of unusual association with prolonged fever. One mg/kg/day prednisone is ineffective in treating FUMHD. We recommend combining 2 mg/kg/day prednisone with IVIG as a starting successful therapeutic regimen of such a life threatening illness.

REFERENCES

- [1] Nofal A, Assaf M, Alakad R, et al. Febrile ulceronecrotic Mucha-Habermann disease: proposed diagnostic criteria and therapeutic evaluation. *International journal of dermatology*. 2016; 55 (7):729-38.
- [2] Nofal A, Alakad R, Assaf M, et al. A fatal case of febrile ulceronecrotic Mucha-Habermann disease in a child. *JAAD case reports*. 2016; 2(2):181.
- [3] Ersoy-Evans S, Greco MF, Mancini AJ, et al. Pityriasis lichenoides in childhood: a retrospective review of 124 patients. *Journal of the American Academy of Dermatology*. 2007; 56 (2):205-10.
- [4] Fernandes NF, Rozdeba PJ, Schwartz RA, et al. Pityriasis lichenoides et varioliformis acuta: a disease spectrum. *International journal of dermatology*. 2010; 49 (3):257-61.
- [5] Khachemoune A, Blyumin ML. Pityriasis lichenoides. *American journal of clinical dermatology*. 2007;8(1):29-36.
- [6] Geller L, Antonov NK, Lauren CT, et al. Pityriasis lichenoides in childhood: review of clinical presentation and treatment options. *Pediatric dermatology*. 2015; 32 (5):579-92.
- [7] Boos M, Samimi S. *Lymphoproliferative Disorders of the Skin. Skin Tumors and Reactions to Cancer Therapy in Children*: Springer; 2018. p. 35-52.
- [8] Perrin BS, Yan AC, Treat JR. Febrile ulceronecrotic Mucha-Habermann disease in a 34-month-old boy: a case report and review of the literature. *Pediatric dermatology*. 2012; 29 (1):53-8.

- [9] Tsianakas A, Hoeger P. Transition of pityriasis lichenoides et varioliformis acuta to febrile ulceronecrotic Mucha–Habermann disease is associated with elevated serum tumour necrosis factor- α . *British Journal of Dermatology*. 2005; 152 (4):794-9.
- [10] Hervás JA, Martín-Santiago A, Hervás D, et al. Varicella precipitating febrile ulceronecrotic Mucha-Habermann disease. *Pediatric dermatology*. 2013; 30 (6):e216-e7.
- [11] Smith JJ, Oliver GF. Febrile ulceronecrotic Mucha–Habermann disease associated with herpes simplex virus type 2. *Journal of the American Academy of Dermatology*. 2009;60 (1):149-52.
- [12] Chao-Chun Y, LEE JYY, WenChieh C. Febrile ulceronecrotic Mucha-Habermann disease with extensive skin necrosis in intertriginous areas. *European Journal of Dermatology*. 2003; 13 (5):493-6.
- [13] Kaufman WS, McNamara EK, Curtis AR, et al. Febrile Ulceronecrotic Mucha-Habermann Disease (Pityriasis Lichenoides et Varioliformis Acuta Fulminans) Presenting as Stevens-Johnson Syndrome. *Pediatric dermatology*. 2012;29 (2):135-40.
- [14] Bowers S, Warshaw EM. Pityriasis lichenoides and its subtypes. *Journal of the American Academy of Dermatology*. 2006; 55 (4):557-72.
- [15] Griffith-Bauer K, Leitenberger SL, Krol A. Febrile Ulceronecrotic Mucha–Habermann Disease: Two Cases with Excellent Response to Methotrexate. *Pediatric dermatology*. 2015; 32(6):e307-e8.
- [16] Zhang Lx, Liang Y, Liu Y, et al. Febrile Ulceronecrotic Mucha-Habermann’s Disease with Pulmonary Involvement. *Pediatric dermatology*. 2010; 27(3):290-3.
- [17] Meziane L, Caudron A, Dhaille F, et al. Febrile ulceronecrotic Mucha-Habermann disease: treatment with infliximab and intravenous immunoglobulins and review of the literature. *Dermatology*. 2012; 225(4):344-8.
- [18] Marengo F, Fava P, Fierro MT, et al. High-dose immunoglobulines and extracorporeal photochemotherapy in the treatment of febrile ulceronecrotic Mucha- Habermann disease. *Dermatologic therapy*. 2010; 23 (4):419-22

Citation: Ayman Mahran, et.al, *Psoriasiform Febrile Ulceronecrotic Mucha Habermann Disease: A New Clinical Presentation of a Case Report from Upper Egypt*. *ARC Journal of Dermatology*. 2019; 4(2):1-4. doi:dx.doi.org/10.20431/2456-0022.0402001.

Copyright: © 2019 Authors. This is an open-access article distributed under the terms of the Creative Commons Attribution License, which permits unrestricted use, distribution, and reproduction in any medium, provided the original author and source are credited.