

Aflibercept in the Management of Bilateral Irvine-Gass Syndrome Triggered by Influenza Vaccine – Case Report

G. H. P. Souto^{1*}, A. B. V. Nepomuceno², J. L. M. Ferreira³

¹Medical student, Christus University Center (Unichristus) – Fortaleza, Ceará, Brazil

²MD, PhD, Reference Center for Ophthalmology (Centro Avançado de Retina e Catarata) – Fortaleza, Ceará, Brazil

³MD, PhD, Professor at the Faculty of Medicine, Christus University Center (Unichristus) – Fortaleza, Ceará, Brazil

***Corresponding Author:** G. H. P. Souto, Medical student, Christus University Center (Unichristus) – Fortaleza, Ceará, Brazil

Abstract: A 62-year-old woman, without comorbidities, in the postoperative period (PP) of phacoemulsification (PHACO), had her ophthalmological examination normal in the third week of PP. However, after the seventh day of influenza virus vaccination, she developed an important complaint of bilateral low visual acuity due to cystoid macular edema (CME), and there was no other triggering factor. As there was no improvement in the condition with non-invasive treatment (anti-inflammatory eyedrops), we opted for treatment with intravitreal injections of antiangiogenic (Aflibercept), considering that CME causes visual impairment, which can be reversible or permanent. It is important to consider influenza vaccine as possible causative or triggering agent for the development of CME in patients undergoing uncomplicated PHACO, because, even if the patient does not have systemic diseases, which increase the production of cytokines, it is essential that health professionals recommend to their patients that they try to avoid, if possible, vaccination in the PP of invasive eye procedures, ensuring greater safety for the patient's recovery. Another relevant fact of this report was the application use of intravitreal Aflibercept in the successful treatment (CVA of 20/20) of bilateral CME refractory to the use of topical non-steroidal anti-inflammatory drugs.

Keywords: Macular Edema; Vision, Low; Angiogenesis Inhibitors; Influenza Vaccines; Case Report.

1. INTRODUCTION

In Brazil, the composition of influenza vaccines, used since February 2019, was disclosed by the National Health Surveillance Agency (ANVISA) in Resolution-RE N° 2.714, of October 4, 2018 (published in the Federal Official Gazette N° 193, of October 5, 2018). It was inactivated influenza-trivalent vaccines containing three types of virus strains in combination and within the following specifications: A/Michigan/45/2015 (H1N1) pdm09; A/Switzerland/ 8060/2017 (H3N2); B/Colorado/ 06/2017 (line B/Victoria/2/87.20) [1,2].

It is important to consider that the adverse events, after influenza vaccination, are general disorders (fatigue, loss of appetite, chills, sweating, indisposition and fever $\geq 37.5^{\circ}\text{C}$); manifestations at the application site (pain, edema, induration, erythema, itching and hematoma); changes in the nervous system

(headache, drowsiness, dizziness, seizures, neuritis, acute disseminated encephalomyelitis, paresthesia, facial paralysis, syncope, transverse myelitis and Guillain-Barré syndrome); psychiatric disorders (agitation and irritability); gastrointestinal involvement (nausea, vomiting, diarrhea and abdominal pain); damages to skin and subcutaneous tissue (erythema, urticaria, angioedema, rash and Stevens-Johnson syndrome); musculo-skeletal involvement (myalgia, arthralgia and tremors); disorders of the immune, blood or lymphatic system (allergic or hypersensitivity reactions, transient lymphadenopathy and thrombocytopenia) and respiratory disorders (dyspnea, pharyngitis, rhinitis and cough). As ocular disorders, there is a description of ocular redness due to conjunctival hyperemia [1].

Cystoid macular edema (CME) is associated with the release of inflammatory mediators by

the epithelial cells of the lens and uveal tissue in the anterior segment of the eye which, if the mediators diffuse into the vitreous and retina, may cause local vasodilation and rupture of the blood-retinal barrier, increasing vascular permeability, which favors the formation of cysts in the macula, contributing to the appearance of CME. This occurs in patients with history of previous retinal diseases, diabetes, uveitis and after cataract surgery, and whose prevalence increases with age [3]. Bilateral Irvine-Gass syndrome, after uncomplicated phacoemulsification (PHACO), is rare, especially when not associated with systemic diseases [4].

Aflibercept is a recombinant fusion protein that consists of portions of the extracellular domains of human endothelial vascular growth factor (VEGF) receptors 1 and 2, which are fused to the Fc portion of human IgG1 immunoglobulin, blocking the activity of factors known as VEGF-A and placental growth factor and, thus, acts to improve retinal vascular permeability, consequently reducing macular edema [3].

In view of the rarity of publications regarding the intraocular adverse effects resulting from the flu vaccine, the present report describes a case of extensive CME post-influenza vaccine, and response to use of Aflibercept in the management of this disorder.

2. CASE REPORT

A 62-year-old Caucasian female patient, without systemic comorbidities, with a history of consecutive, uncomplicated, cataract surgery using the PHACO technique, with intraocular lens implantation. PHACO occurred on May 2, 2019 in the right eye (RE) and on May 14, 2019 in the left eye (LE), without complications, and the patient reported the proper use of the postoperative eyedrops, as prescribed routine, namely: gatifloxacin 0.3% associated with prednisolone acetate 1% (Zypred[®], Allergan, Inc.) every two hours (in a weaning scheme every three days) and ketorolac trometamol 0.4% (Acular[®] LS, Allergan, Inc.) every six hours (for 60 days). On May 22, 2019, had corrected visual acuity (CVA) of 20/20 in both eyes, without macular edema and was satisfied with the surgical and visual results.

On May 24, 2019, the patient used an anti-influenza vaccine, provided by the public

health network, during the 21st national flu vaccination campaign in Brazil. On the seventh day after vaccination, she complained of sudden, simultaneous low visual acuity (LVA), with progressive worsening of vision far and near, accompanied by metamorphopsia in both eyes. The patient was still using non-steroidal anti-inflammatory therapy (NSAID) with ketorolac trometamol 0.4% in both eyes. On ophthalmological examination, CVA was 20/150 in RE and 20/60 in LE; biomicroscopy without changes; intraocular pressure (IOP) of 15 mmHg in both eyes; normal gonioscopy and funduscopy revealed extensive bilateral CME, confirmed by fluorescent angiography (Figure 1) and optical coherence spectral domain-tomography (SD-OCT) (Spectralis OCT, Heidelberg Engineering, Inc., Carlsbad, CA), but the first OCT was performed in the time domain (Stratus OCT, Carl Zeiss Meditec, Inc.) (Figure 2). Infectious, immunological, and hematological etiologies were investigated, revealing negative results for these possible most common causes of CME. The conduct was to continue using the NSAID eye drops.

As treatment with NSAID eye drops did not improve the clinical condition, and the exams showed the persistence of bilateral CME, we opted for treatment with intravitreal Aflibercept (2mg/0.05cc Eylea[®]; Regeneron Pharmaceuticals Inc., Rensselaer, New York, USA and Bayer, Berlin, Germany) in both eyes, three applications, with one monthly interval, culminating in the complete resolution of macular edema in LE (Figure 3) and an important reduction of edema in RE (Figure 4). In view of this finding, two more applications of Aflibercept in RE were indicated, evolving with complete and permanent resolution of CME (Figure 5) and CVA partial 20/20 in RE and 20/20 in LE. There were no ocular or systemic complications related to intravitreal injections.

3. DISCUSSION

Long-term CME causes irreversible changes in the retinal layers, leading to a permanent deficit in visual function. The main anatomical damage caused by chronic CME is linked to changes in the external limiting membrane, photoreceptor segments (thinning of the external nuclear layer and atrophy of the external segment) and disorganization of the internal retinal layers. For these reasons,

treatment should be carried out as soon as possible, to avoid structural changes in the retina and irreversible damage to visual function [5], corroborating the excellent result of the case described here.

Corticosteroids are the basis for the therapy of inflammatory macular edema, because of their potent and fast-acting anti-inflammatory properties. However, its use has not been so recommended, due to systemic and ocular side effects, such as cataracts, increased intraocular pressure and greater risk of progressing to more severe conditions, in the event of an opportunistic eye infection by fungi or viruses [6]. In the literature, there are descriptions of patients with recalcitrant inflammatory macular edema, who obtained significant worsening of vision, after being medicated with topical and/or systemic use of anti-inflammatory drugs, and even after intravitreal injections of triamcinolone, and who, after intravitreal injection of bevacizumab, evolved with a statistically significant improvement in retinal thickening in these patients with persistent CME [5], thus evidenced by the change in conduct and resolution of our patient's clinical condition.

Anti-VEGF is less likely to cause progression of cataracts or glaucoma. It is prepared in solution with no known component that could be harmful to the retina. In a meta-analysis, with four studies and 124 eyes, there was no difference in the nerve fiber layer (NFL) after six months of using anti-VEGF, although for longer periods, such as after 12 months, a small but significant reduction of NFL[5]. In case, we opted for the use of anti-VEGF (Aflibercept), as another therapeutic option, which can avoid the most common complications of the use of intravitreal corticosteroids [3,6].

Macular edema results from pathological hyperpermeability of the retinal blood capillaries. The increase in vascular permeability results in leakage of fluid, proteins, and other macromolecules to the retinal interstice [3]. Vascular hyperpermeability, which favors the appearance of CME, can be induced by many molecules, such as prostaglandins, protein kinase C, VEGF, tumor necrosis factor alpha and interleukins [6].

Even with all improvements in the surgical technique, cataract surgery can release inflammatory mediators, mainly in the first three months after surgery, with a higher incidence in the first four to six weeks, being therefore considered an important cause of LVA due to macular involvement. According to studies, CME is considered the main complication of PHACO, corresponding to 23% of non-diabetic individuals undergoing uncomplicated cataract surgery, with most cases being self-limited, and only 0% to 6% of these patients can report significant complaints of LVA due to extensive maculopathy⁴. In addition, studies demonstrate that the use of NSAID after PHACO acts as a prophylaxis for this macular damage[5]. Bearing in mind that the patient was using eyedrops after PHACO, as a prophylaxis of CME, it is believed that the vaccination factor precipitated a systemic inflammatory process, adding to the fact that she was in the post-operative period of PHACO (RE had 22 days and LE for 10 days), triggering the bilateral and simultaneous CME Irvine-Gass, perceived by the patient on the seventh post-vaccine day.

The fact that the influenza vaccine is composed of an inactivated virus may have generated security for the patient, and her ophthalmologist, to be vaccinated, since PHACO was a success and her CVA was 20/20 in both eyes. The influenza vaccine, even though it is an inactivated virus vaccine, that is, it does not present the risk of causing the flu condition fully, has systemic side effects, which affect 1% to 2% of the vaccines, which are related to the formation mechanism of the memory immune system, which involves the intensification of the inflammatory process, with consequent release of cytokines [7]. Published case reports described the occurrence of visual impairment, post-influenza vaccine, such as: acute macular neuroretinopathy [8], optic neuropathy [9], acute multifocal epitheliopathy due to posterior placoid pigment [10], Vogt-Koyanagi-Harada syndrome [11] and retinal vasculitis [12]. For this reason, it is important that, in the face of a patient without systemic comorbidities, and with LVA by CME, after cataract surgery, other reasons that may lead to such complication are considered and investigated, with a recent influenza vaccine history being one of possible reasons to consider.

In the world literature, only one case report of bilateral macular edema was described in 1971, due to an immediate hypersensitivity reaction to the pollen vaccine, and the LVA symptom was referred to on the same day as the vaccine application, followed by headache, stiffness neck and extreme lethargy, typifying a strong allergic reaction to the Pollen vaccine [7]. This was different from the present case report, because the patient did not present any symptoms in the first days after vaccination, having the only complaint of LVA from the seventh day after vaccination against influenza. This likely relationship between the influenza vaccine and the development of extensive CME is not well established. In the scientific community, only one case report was cited suggesting this relationship, which was published in 1991, however, unlike the present case, it was a case of CME post-influenza vaccine in only one eye in post-cataract surgery [13].

There is no consensus about the most effective treatment for CME, due to the limited clinical trials controlled by placebo, double-masked and randomized for treat this pathology. We know that the topical administration of medications for treat diseases in the posterior segment brings greater comfort to the patient, but there is a limitation regarding the penetration of the drug in the posterior segment, causing the failure of the ketorolac trometamol 0.4 % eye drops used in the present report. The delay in resolving macular edema can transform it into chronic macular edema and, thus, compromise the final visual prognosis, evolving with macular hypotrophy and permanent visual impairment[3].

The treatment of extensive CME consists of avoiding the continuation of inflammation, currently using intravitreal antiangiogenic as the main management, which supports the improvement of visual acuity [3]. Although no

randomized controlled clinical trial has Aflibercept's ability to treat CME is reported, there is evidence that this drug has promising activity against macular edema of varying etiologies. Previous reports [3,5] suggest that intravitreal Aflibercept would present a favorable performance, compared to conventional NSAID, in the treatment of CME. Thus, it can be another resource for treat this pathology, especially in patients refractory to NSAID eye drops, or who have contraindications to the use of corticosteroids, because they are phakic or because they have a previous history of glaucoma [6].

It is worth discussing, as a weak point of the present case report, the fact that the OCT was performed on different devices, in which the first OCT, at the beginning of the CME, was performed with the time-domain OCT stratus, while the serials, for monitoring the treatment, were performed in the SD-OCT. However, this fact did not diminish the merit of this publication, since there are studies that demonstrate a comparative relevance between these two technologies, in addition to highlighting the fact that the most accurate technique was used in the accompanying OCT, increasing the detection of possible retinal damage [5].

4. CONCLUSION

The present case report brings to the attention of the scientific community a case that has not yet been reported and, above all, is committed to alerting surgeon ophthalmologists so that their patients are cautious about the use of vaccines during the postoperative recovery period. We encourage these professionals to consider influenza vaccine as a cause of CME Irvine-Gass, including adding this information to the package insert for this vaccine, for the knowledge of the patient and other health professionals.

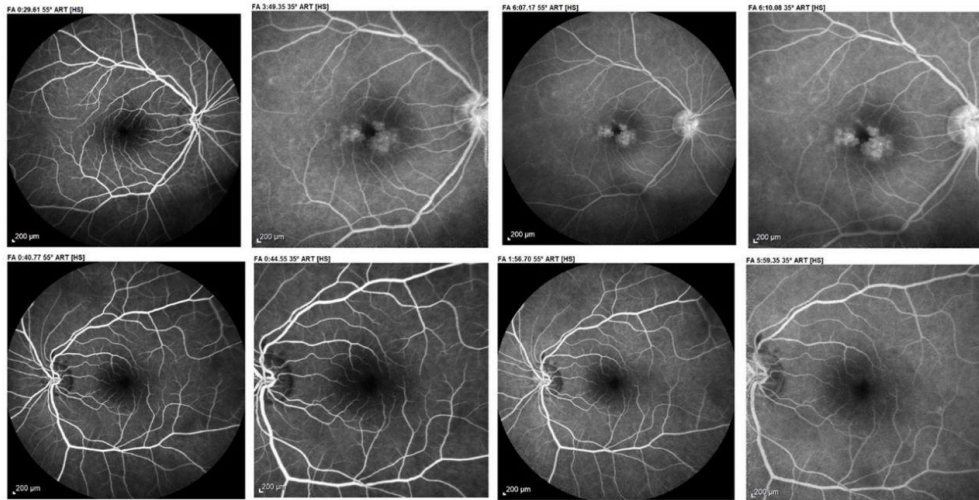


Figure1. Fluorescent angiography rules out signs of vasculitis, confirm the diagnosis of bilateral cystoid macular edema, especially in the right eye (RE), which shows late hyperfluorescence in optical disc, compatible with concomitant papillitis in RE.

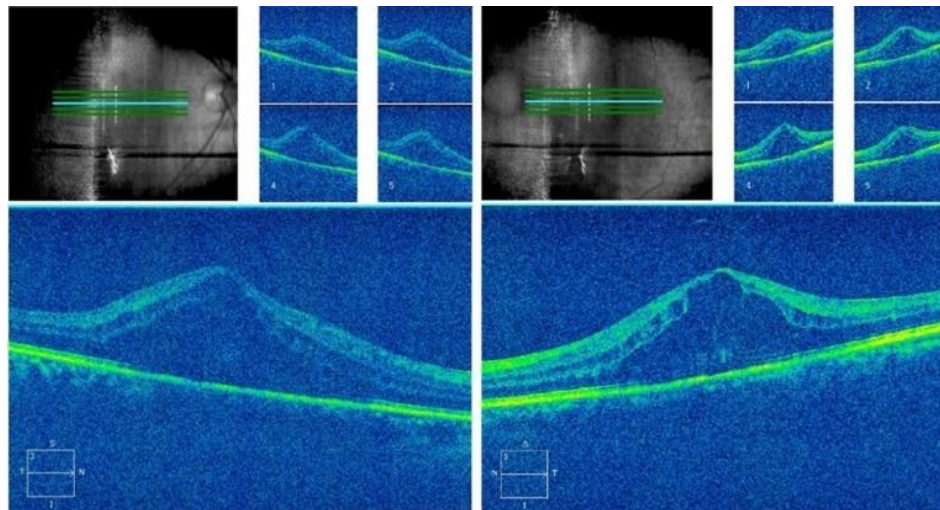


Figure2. On the 7th day after influenza vaccination, the patient reported bilateral sudden and simultaneous visual impairment, and, during the OCT exam, we noticed significant macular edema, loss of the foveal contour and the presence of multiple intraretinal cysts.

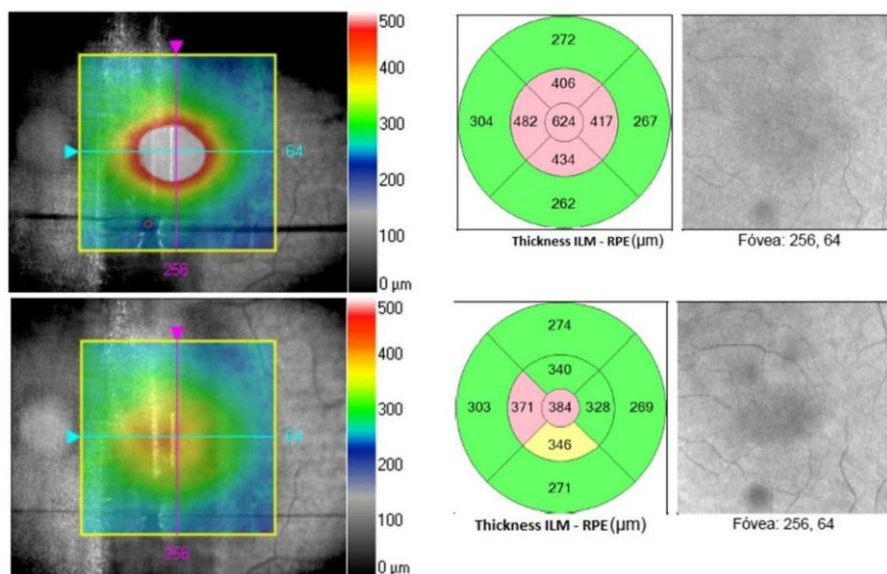


Figure3. Improvement of macular edema after 1st Aflibercept to left eye.

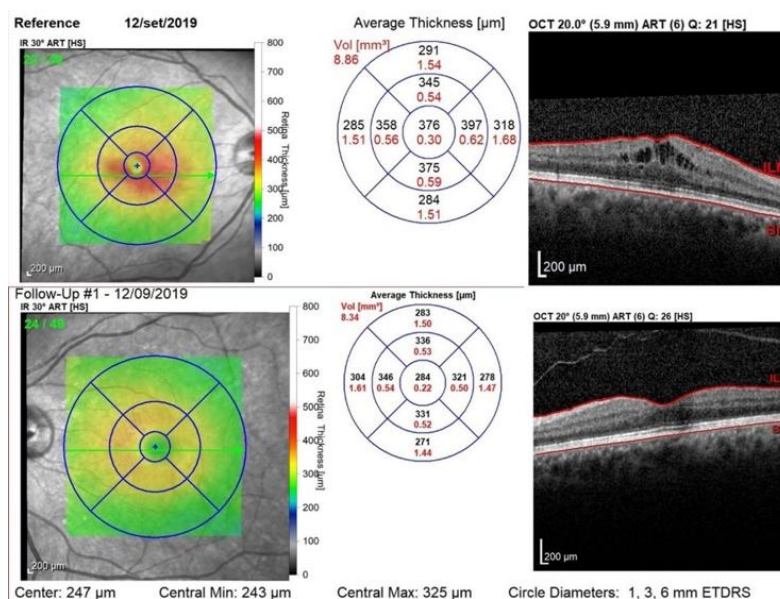


Figure4. After three consecutive Aflibercept in both eyes, we obtained a significant reduction in macular edema in the right eye and complete resolution of macular edema in the left eye.

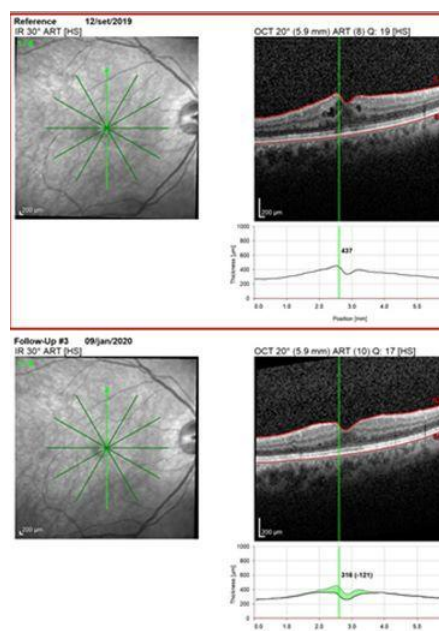


Figure5. After two additional applications of Aflibercept in the right eye only, we have also achieved complete resolution of cystoid macular edema in this eye.

REFERENCES

- [1] Brazil. Ministério da Saúde. Informe técnico. 21ª Campanha Nacional de Vacinação contra Influenza. Access in: <https://portalarquivos2.saude.gov.br/images/pdf/2019/fevereiro/28/Informe-Cp-Influenza-28-02-2019-final.pdf>
- [2] Anvisa. Brazil. Ministério da Saúde. Imunização 2019. Definida composição da vacina contra a influenza. Access in: <https://www.gov.br/anvisa/pt-br/assuntos/noticias-anvisa/2018/definida-composicao-da-vacina-contra-a-influenza>
- [3] Lin CJ, Tsai YY. Use of aflibercept for the management of refractory pseudophakic macular edema in Irvine-Gass syndrome and literature review. Retin Cases Brief Rep. 2018; 12(1):59-62.
- [4] Shields MK, Adler PA, Fuzzard DR, Chalasani R, Teong JM. A Case of Acute Bilateral Irvine-Gass Syndrome following Uncomplicated Phacoemulsification, Demonstrated with Optical Coherence Tomography. Case Rep Ophthalmol. 2015; 6 (1): 143-148.
- [5] Nepomuceno AB, Takaki E, Paes de Almeida FP, et al. A prospective randomized trial of intravitreal bevacizumab versus ranibizumab for the management of diabetic macular edema. Am J Ophthalmol. 2013; 156 (3): 502-510.e2.

- [6] Van Kooij B, Rothova A, de Vries P. The pros and cons of intravitreal triamcinolone injections for uveitis and inflammatory cystoid macular edema. *Ocul Immunol Inflamm.* 2006; 14:73-85.
- [7] Dugmore, WN. Bilateral oedema at the posterior pole. Hypersensitivity reaction to Alavac P injection. *Br J Ophthalmol.* 1971; 55 (12): 848-849.
- [8] Liu JC, Nesper PL, Fawzi AA, et al. Acute macular neuroretinopathy associated with influenza vaccination with decreased flow at the deep capillary plexus on OCT angiography. *Am J Ophthalmol Case Rep.* 2018; 10:96-100.
- [9] Papke D, McNussen PJ, Rasheed M, et al. A Case of Unilateral Optic Neuropathy Following Influenza Vaccination. *Semin Ophthalmol.* 2017; 32(4):517-523.
- [10] Gonome T, Suzuki Y, Metoki T, et al. Acute posterior multifocal placoid pigment epitheliopathy and granulomatous uveitis following influenza vaccination. *Am J Ophthalmol Case Rep.* 2016; 4:60-63.
- [11] Kim M. Vogt-Koyanagi-Harada Syndrome following influenza vaccination. *Indian J Ophthalmol.* 2016; 64(1):98.
- [12] Cheung AY, Anderson B, Stec L, et al. Bilateral vaso-occlusive retinal vasculitis with h1n1 influenza A infection. *Retin Cases Brief Rep.* 2015;9(2):138-41.
- [13] Knopf HL. Recurrent uveitis after influenza vaccination. *Ann Ophthalmol.* 1991; 23(6):213-214.

Citation: G. H. P. Souto, A. B. V. Nepomuceno, J. L. M. Ferreira. "Aflibercept in the Management of Bilateral Irvine-Gass Syndrome Triggered by Influenza Vaccine – Case Report" *ARC Journal of Clinical Case Reports*, vol 9, no.2, 2023, pp. 5-11. DOI: <https://doi.org/10.20431/2455-9806.0902002>.

Copyright: © 2023 Authors. This is an open-access article distributed under the terms of the Creative Commons Attribution License, which permits unrestricted use, distribution, and reproduction in any medium, provided the original author and source are credited.