

## ***Mansonella perstans* Mansonellosis in a Three Years Old Child with Tetralogy of Fallot: a Case Report**

Victor Mwanakasale (MD)<sup>1\*</sup>, NataliyaYakovlevya (MD)<sup>2</sup>, Memory C Kalolekesha(MSc)<sup>1</sup>, Chitalu Musonda (BSc)<sup>3</sup>

<sup>1</sup>Copperbelt University, Michael Chilufya Sata School of Medicine, Ndola, Zambia

<sup>2</sup>Ndola Teaching Hospital, Ndola, Zambia

<sup>3</sup>Chilonga Mission Hospital, Mpika, Zambia

**\*Corresponding Author:** Victor Mwanakasale (MD), Copperbelt University, Michael Chilufya Sata School of Medicine, Ndola, Zambia

**Abstract:** We present a case of *Mansonella perstans* mansonellosis in a three years old child who was a confirmed case of Tetralogy of Fallot. We urge more research to identify effective chemotherapy for this infection and more epidemiological studies to fill gaps in the current knowledge about the transmission patterns of *Mansonella perstans*.

**Keywords:** Tetralogy, Fallot, Mansonellosis, Neglected, Epidemiology, Chemotherapy.

### **1. INTRODUCTION**

Tetralogy of Fallot (TOF) is one of the commonest forms of cyanotic congenital heart disease [1]. It accounts for 7-10% of all congenital cardiac malformations with an incidence of 1 in 3,500 live births [2]. TOF is characterized by four cardinal features: Ventricular Septal Defect (VSD); Right Ventricular (RV) outflow tract obstruction (RVOTO), also referred to as Pulmonary stenosis, which is often dynamic; an overriding Aorta; and Right Ventricular Hypertrophy (RVH) [2]. A key feature of TOF is the obstruction to the pulmonary blood flow at the level of the right ventricle outflow tract. The RVOTO subsequently causes the RVH which is another key feature of TOF. In the absence of an unrestrictive VSD, worsening RVOTO increases the RV pressure, drives a right-to left shunt through the VSD, reduces pulmonary blood flow, and leads to hypoxaemia.

There are a number of subtypes of TOF, largely distributed by the degree of cyanosis displayed [3]. TOF symptoms and signs vary, depending on the amount of blood flow that is blocked. The clinical features of TOP include cyanosis (maybe gradual onset and increasing in severity or with age), hypoxia/low saturation of peripheral oxygen (SPO<sub>2</sub>)with

little or no response to oxygen therapy, heart murmurs (pansystolic and ejection systolic), spelling episode, also known as hypercyanotic episode (agitated, distressed, profound cyanosis), arrhythmias (particularly supraventricular or ventricular), and associated features of other genetic abnormalities [4]. Features of late presentation of TOF may include poor exercise tolerance, clubbing, polycythemia, neurodevelopmental delay, failure to thrive, heart failure, recurrent respiratory tract infections, and cerebral abscess and stroke. TOF is managed by surgical repair [5,6].

*Mansonella perstans* mansonellosis is considered to be the most prevalent filariasis in Africa, distributed mostly in wet subtropical and tropical areas of Africa [7]. Infection is transmitted to humans by the bite of infected biting midges belonging to the genus *Culicoides* spp. Body heat activates the larva (L<sub>3</sub>, also called filariform larva) to leave the vector and actively penetrate the bite wound and mature into adult worms [8]. In infected humans the adult worms may be found in the pericardium, pleura, peritoneum, mesentery and retroperitoneum. Most of mansonellosis cases are asymptomatic with eosinophilia being a common feature. Where symptoms do occur they are non-specific and include pruritus, urticarial, arthralgia, abdominal pain,

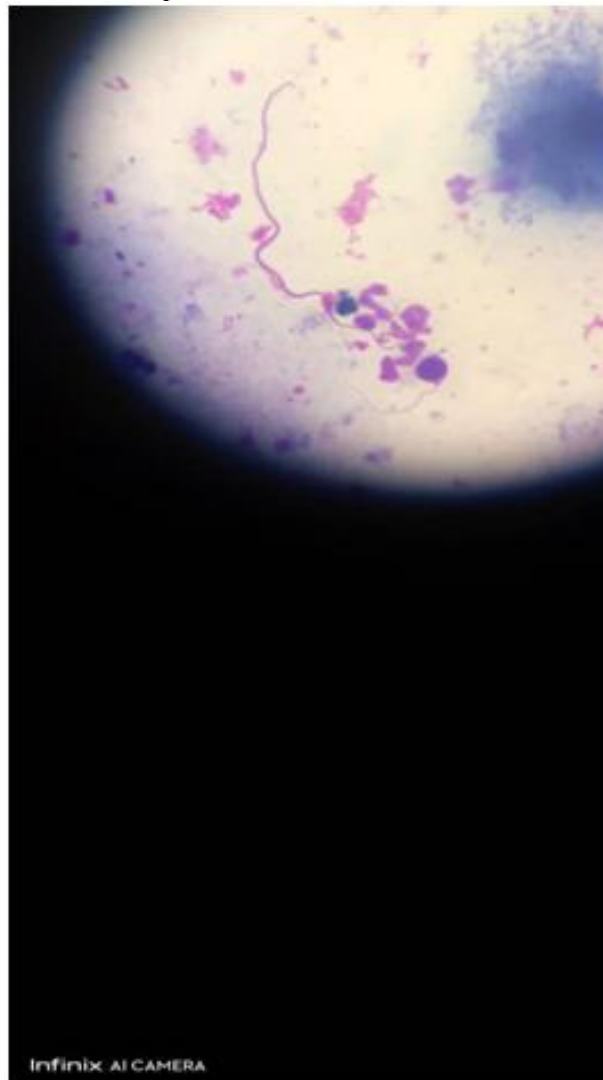
and fatigue [9]. Symptoms of infection may probably be related to the migration of the adult worms and may include transient subcutaneous swellings, similar to the Calabar swelling (caused by *Loa loa*), pericarditis, pleuritic, and inflammatory granulomatous nodules surrounding dead adult worms [10]. Diagnosis of *M.perstans* is by detecting the microfilariae in Giemsa-stained blood smear. The microfilariae are 190-200 µm long and the nuclei extend to the tip of the tail, which is blunt. None of the available antihelminthic drugs have any efficacy against *M.perstans* Mansonellosis.

We present a case of a child that had Tetralogy of Fallot and diagnosed with *M.perstans* mansonellosis.

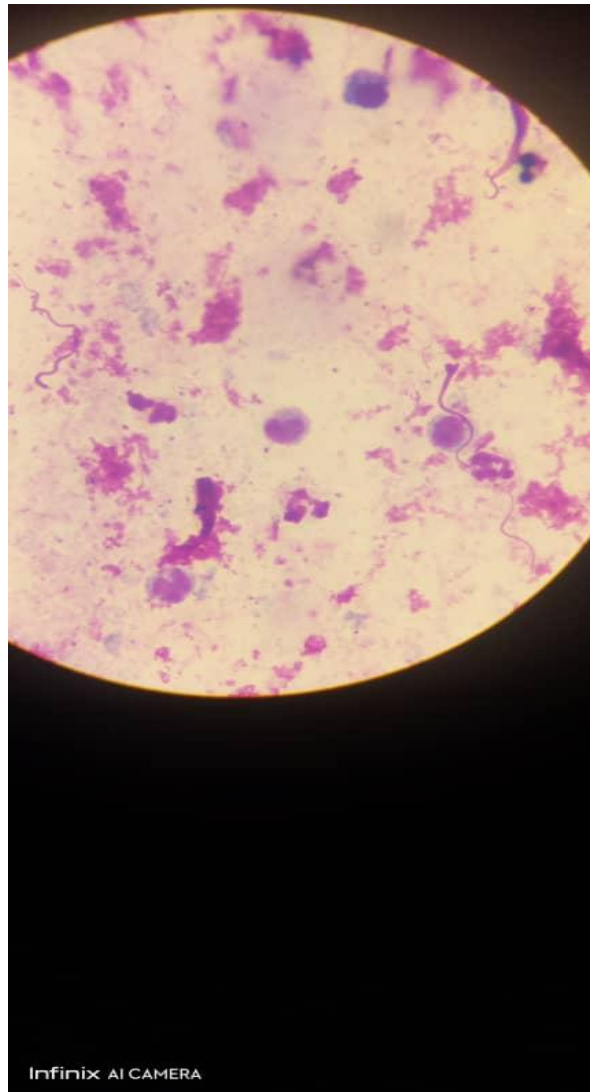
## 2. THE CASE

A three years old girl who was a confirmed case of Tetralogy of Fallot (TOF), was routinely reviewed at a rural hospital in

Zambia on a particular day in February 2023. The patient resided in an area endemic of Human African Trypanosomiasis in Muchinga province of Zambia. On physical examination, the patient had the signs of TOF that included cyanosis, clubbing of fingers, and systolic ejection murmur. A peripheral blood examination for malaria parasites was requested on the patient as a routine checkup. A thick blood film was prepared and stained with giemsa stain and examined. The blood examination revealed the presence of microfilariae of *Mansonella perstans* (Figures 1 and 2). No malaria parasites were seen on the blood film examination. A diagnosis of *M.perstans* mansonellosis in TOF was made. No drug was given to the patient to treat this infection as there is no known effective chemotherapy for mansonellosis. The patient continued receiving treatment for TOF as she awaited referral to the National Cardiac Hospital for corrective cardiac surgery.



**Figure1.** Microfilaria of *Mansonella perstans* on a Giemsa stained thick blood film (X 100 objective)



**Figure2.** *Microfilaria of Mansonella perstans* on a Giemsa stained thick blood film, another view (X 100 objective).

### 3. DISCUSSION

The prevalence of *M. perstans* mansonellosis in children with TOF in Africa is unknown. This is because the infection is not routinely examined for in cases of confirmed TOF cases. Whereas the management of TOF is known [2], there is no known chemotherapy for *M. perstans* mansonellosis. Some efficacy with Doxycycline was demonstrated targeting a Wolbachia endosymbiont [11]. Drugs such as Ivermectin and Diethyl Carbamazine (DEC) that are known to be effective in the treatment of filarial worm infections such as Lymphatic filariasis and Onchocerciasis have been proven to be ineffective in the treatment of mansonellosis caused by *Mansonella ozzardi* and *Mansonella streptocerca* [12, 13]. This implies that both Ivermectin and DEC are ineffective in the treatment of *M. perstans* mansonellosis. *M. perstans* mansonellosis is not even listed among the neglected diseases of

the World Health Organization (WHO) and no control strategy has been designed for it. It could be argued that the major reasons for this lack of attention given to Mansonellosis in general is that these infections are prevalent in poor and rural populations of the world, they are not associated with distinct clinical features, and that there is currently no drug that could be used in community-directed treatment against them [8]. Because adult worms of *M. perstans* can be found in the pericardium and lead to pericarditis, *M. perstans* mansonellosis in cases of TOF should be treated with effective chemotherapy and monitored carefully to rule out any complications of TOF management.

### 4. CONCLUSION AND RECOMMENDATIONS

*Mansonella perstans* mansonellosis is a neglected tropical infectious disease that needs urgent attention by the world health authorities especially when it is detected in children with

congenital cardiac disorders such as Tetralogy of Fallot. Involvement of the pericardium in *M.perstans* mansonellosis could complicate outcome of management of TOF in children with both conditions. There is need to develop effective chemotherapy, design effective control strategies, and collect more data on the epidemiology for *M.perstans* mansonellosis.

## 5. ACKNOWLEDGEMENT

We wish to thank Professor Paul Chisale, the Vice Chancellor of Copperbelt University, for having approved this work. We are also grateful to the laboratory technical staff at the rural hospital that shared the laboratory findings for our patient with us.

## REFERENCES

- [1] Villafane J, Feinstein JA, Jenkins KJ. Hot topics in Tetralogy of Fallot. *J Am CollCardiol.* 62, 2155-2166 (2013).
- [2] Wilson R, Ross O, Griksaitis MJ. Tetralogy of Fallot. *BJA Educ.* Nov; 19(11), 362-369 (2019).
- [3] Baillard F, Anderson R. Tetralogy of Fallot. *Orphanet J Rare Dis.* 4, 2 (2009).
- [4] Kramer HH, Majewski F, Trampisch HJ, Rammos S, Bourgeois M. Malformation patterns in children with congenital heart disease.
- [5] Hirsch JC, Mosca RS, Bove EL. Complete repair of Tetralogy of Fallot in the neonate: results of the modern era. *Ann Surg.* 232, 508-514 (2000).
- [6] Gatzoulis K, Frogoudaki A, Brili S, Stefanadis C. implantable defibrillators: from the adult cardiac to the grown up congenital heart disease patient. *Int J Cardiol.* 97, 117-122 (2004).
- [7] Tavares da Silva LB, Grainey JL, Ribeiro da Silva TR, Suwa UF, Vicente AC, Fernandes de MJ. Molecular verification of new world *Mansonellaperstan* sparasitemias. *Emerg Infect Dis.* 23, 545-547 (2017).
- [8] Dyce Sharp NA. *Filariaperstans*; its development in *Culicoidesausteni*. *Trans R Soc Trop Med Hyg.* 21, 371-396 (1928).
- [9] Mediannikov O and Ranque S. Mansonellosis, the most neglected human filariasis. *New Microbes New Infect.* 26, S19-S22.
- [10] Simonsen PE, Onapa AW, Asio SM. *Mansonellaperstans*filariasis in Africa. *Acta Trop.* 120 (Suppl. 1), S109-S120.
- [11] Shelly AJ, Coscaron S. Simuliid blackflies (Diptera: Simuliidae) and Ceratopogonid midges (Diptera: Ceraponidae) as vectors of *Mansonella* spp. (Nematoda: Onchocercidae) in northern Argentina. *Mem Inst Oswaldo Cruz.* 96, 451-458 (2001).
- [12] Coulibaly YI, Dembele B, Diallo AA, Lipner EM, Doumbia SS, Coulibaly SY. A randomized trial of doxycycline for *Mansonella perstans* infection. *N Engl J Med.* 361, 1448-1458 (2009).
- [13] Bartholomwe CE, Nathan MB, Tikasingh ES. The failure of diethyl carbamazine in the treatment of *Mansonella* infections. *Trans R Soc Trop Med Hyg.* 72, 423-424 (1978).

**Citation:** Victor Mwanakasale (MD)\*, NataliyaYakovlevya (MD), Memory C Kaloleksha, Chitalu Musonda (BSc). "Mansonella perstans Mansonellosis in a Three Years Old Child with Tetralogy of Fallot: a Case Report" *ARC Journal of Clinical Case Reports*, vol 9, no.2, 2023, pp. 1-4. DOI: <https://doi.org/10.20431/2455-9806.0902001>.

**Copyright:** © 2023 Authors. This is an open-access article distributed under the terms of the Creative Commons Attribution License, which permits unrestricted use, distribution, and reproduction in any medium, provided the original author and source are credited.