

## The Great Interhemispheric Connection. Could We Function without the Corpus Callosum? Systematic Review and Case Report

Arturo Amed López-Márquez<sup>1\*</sup>, José Flores-Almanza<sup>1</sup>, José Fernando García-Pons<sup>2</sup>,  
Andrés Armendáriz-Rodríguez<sup>3</sup>

<sup>1</sup>Escuela Nacional de Medicina y Homeopatía, Instituto Politécnico Nacional, Mexico City, Mexico.

<sup>2</sup>División de Ciencias de la Salud, Departamento de Medicina y Nutrición, Universidad de Guanajuato, Guanajuato, México.

<sup>3</sup>Surgical resident. Hospital General Balbuena, Secretaría de Salud, Mexico City, Mexico.

**\*Corresponding Author:** Arturo Amed López-Márquez, Escuela Nacional de Medicina y Homeopatía, Instituto Politécnico Nacional, Mexico City, Mexico

**Abstract:** The agenesis of the corpus callosum (ACC) is a congenital anomaly characterized by the absence of its functional and structural development. The prevalence of ACC is surprisingly common; it affects 1 of every 4000 live births in a male-female ratio of 2:1. 30-45% of patients with this condition are identified by prenatal imaging. In this paper, we described a clinical case report: A 12-year-old male attends to the physician because of depression. In the prenatal screening he was diagnosed with ventriculomegaly (or hydrocephalus). He did not present any other congenital anomalies, even those described in similar cases - like facial malformations.

**Keyword:** Agenesis of corpus callosum, corpus callosum, case report, Wechsler scale, neuropsychological tests.

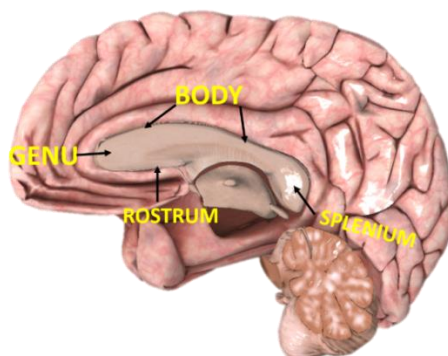
### 1. INTRODUCTION

The corpus callosum (CC) is a brain structure formed of white matter, meaning that it is made up of myelinated axons. It contains about 250 million axons, making the CC the longest transverse commissure in the nervous system.(1)The CC is responsible for the communication of homologous structures among both cerebral hemispheres –which is

why it is also named the central commissure—allowing the brain to work together coherently.

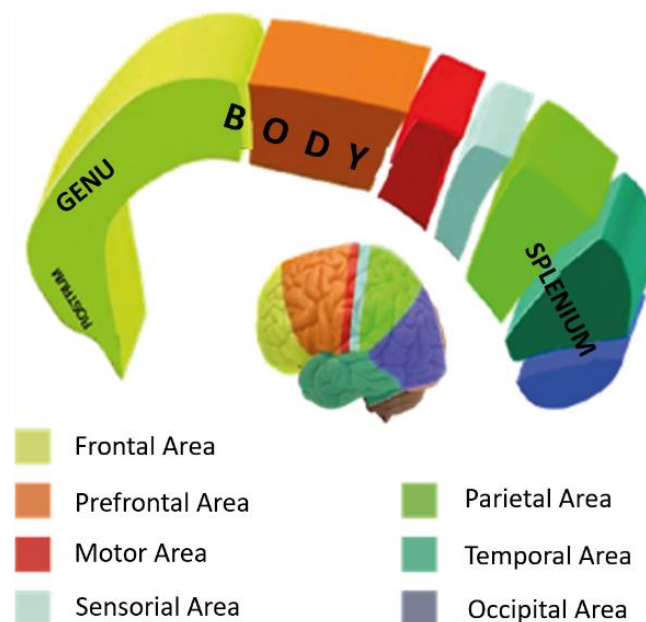
The primary function of the CC is the transmission and coordination of information between our cerebral hemispheres.(2)

Anatomically, we divide the corpus callosum into four portions: rostrum, knee or genu, body, and splenius.(2) Each element of this structure links specific brain areas. (Figure 1.)



**Figure1.** Sagittal section of the brain showing the portions of the corpus callosum

- The rostrum and genu mutually connect the prefrontal cortex, orbitofrontal cortex, medial frontal gyrus, superior frontal gyrus, and anterior cingulate cortex.
- The body connects precentral and postcentralgyri, parietal lobules, superior temporal gyrus, and posterior cingulate cortex
- The splenius connects the occipital lobes, part of the posterior cingulate, temporo-parieto-occipital association cortex, and the inferior temporal region.



**Figure2.** Diagram that illustrates the portions of the CC and their specific brain areas functional correlation

The agenesis of the corpus callosum (ACC) is a congenital anomaly characterized by the absence of its functional and structural development. ACC is mainly associated with other comorbidities like in-utero immunological aggression of the lamina terminalis, prenatal infections, and some chromosomal abnormalities like the Aicardi syndrome.(3–5)

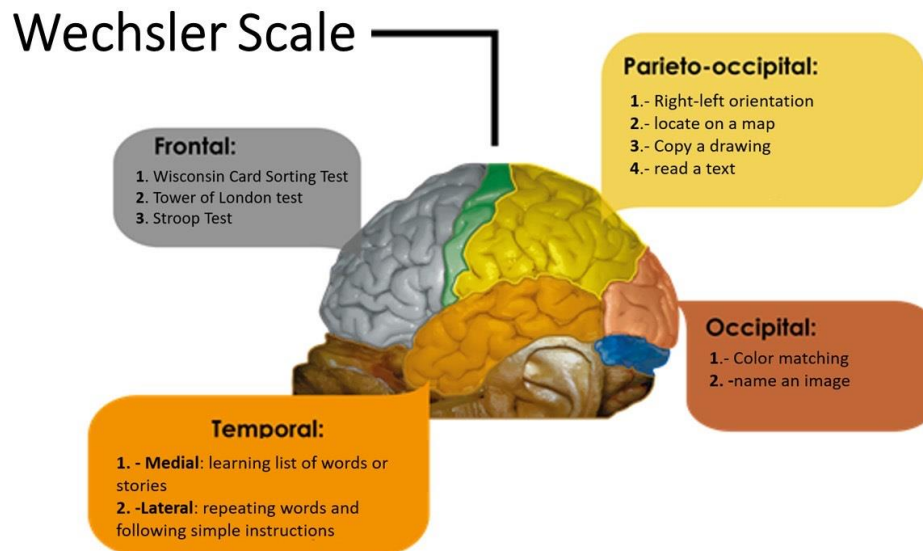
The prevalence of ACC is surprisingly common; it affects 1 of every 4000 live births in a male-female ratio of 2:1. 30-45% of patients with this condition are identified by prenatal imaging.(2)

ACC usually presents with other comorbidities such as apraxia, aphasia, gait disturbances, facial and body malformations, and loss of mental functions.(4,5)

Multiple diagnostic tools are used to evaluate the clinical outcomes of ACC or its dysgenesis. (Fig3)

One of the most frequently used instruments to assess the neuropsychological profile in patients with CC-related pathologies is the Wechsler Intelligence Scale for Children(5–7).This scale measures the intellectual function (IQ) depending on the patient’s cognitive capacities and deficiencies in verbal and perceptual reasoning tasks; at the same time, it also evaluates global cognitive functioning.

The Wechsler Scale assesses the cognitive functions of the entire brain cortex. It serves as an initial test to rule out global cognitive deficits; afterwards, it screens for irregularities in each brain lobe or association area. (Figure 3)



**Figure3.** Illustration of the cerebral lobes and the diagnostic tools used for their neuropsychological evaluation.

A review on the neuropsychological profile of patients with malformations of the CC concluded that around 80% of them had an IQ slightly below average, as well as poor motor coordination, decreased reaction time, and deficiencies in calculation and language (pragmatic) skills.

The Wechsler scale outlines cognitive functions related to the CC, being language a crucial item in the IQ score. In ACC there is an expected decrease in global cognitive functioning; however, an increase in alternate commissures signaling could compensate for the mental functions deficits attributed to the ACC.(7,8)

With this basis, we wonder:

1. Is the CC essential for the functional integrity of the human being?
2. Does neuropsychological testing demonstrate alternate commissures taking over CC functions?
3. Are neuropsychological tests adequate to evaluate patients with ACC?

The objective of this paper is to identify the role of the CC and its pathological association in ACC; and correlate it with the current case report and, in this way establish the efficacy of neuropsychological tests that assess CC-related cognitive functions in patients with ACC.

## 2. METHODS

We searched for case reports and qualitative systematic reviews using multiple databases such as MedLine, Elsevier, and Scielo. We used the keywords: "agenesis of the corpus callosum", "corpus callosum", "case report", "neuropsychology", and "Wechsler". We oriented the search to clinical studies. The current paper has the signature of the patient and/or family within an academically informed consent.

## 3. CLINICAL CASE

A 12-year-old male attends to the physician because of depression. In the prenatal screening he was diagnosed with ventriculomegaly (or hydrocephalus). He did not present any other congenital anomalies, even those described in similar cases -like facial malformations.

The ACC became evident since the prenatal ultrasound screening. The parents thought that the child's peculiar conduct was due to his underlying pathology. However, specialists denied this causality.

Even though the child lacks the structure linking our two cerebral hemispheres, he practices tae-kwon-do and has earned the green belt at 12 years old.

Currently, the child is in his 5th year of elementary school, without showing any pitfalls in his education. He even obtained higher grades than his average peer students.

Figure 3 compares two T1-weighted magnetic resonance images (MRI). The image “A” corresponds to the child’s MRI, and image

“B” shows a normal MRI highlighting the corpus callosum in yellow.

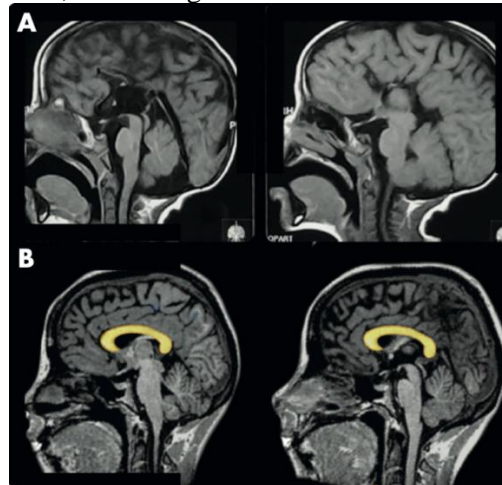


Figure 5. T1-weighted MRI

#### 4. RESULTS

The clinical case presented above showed a child with ACC and isolated ventriculomegaly, without other structural or functional findings. In our literature search, we found just one case series of 3 patients with ACC that did not present alterations in gait, language, motor skills, or psychomotor retardation.(5) However, in this case series, the patients only underwent brain function evaluation (IQ) with the Wechsler scale. They did not use complementary tests for a more extensive assessment of the absent CC. For instance, since the commissural fibers play a critical role in lateralization, the authors could have evaluated dichotic-listening.(9) They also omitted tests for hemisphere dominance like the Wada test.

#### 5. CONCLUSIONS

Based on the case report presented above, we can conclude that:

The lifestyle of patients with ACC could be relatively unaffected, though it may be challenged by cognitive complex tasks, neuropsychiatric disorders and their learning skills (10–12). We propose that the use of neighboring commissures take over some of the communication loss in the absence of CC. Also, the CC could be unrelated to the development of cognitive activities such as higher mental, motor, or somatosensory functions.(7,8,10)

Currently, there are no specific neuropsychological tests developed to assess

cognitive functions in patients with ACC(6). The tests performed in ACC patients assess cognitive function by correlating deficits with normal parameters expected for age.(10,13)

Likewise, we emphasize that early and adequate stimulation may be crucial in functional development, even with ACC.(2,9) The gold-standard diagnostic study in utero is the prenatal ultrasound -available to all Mexicans. An MRI could also be used.(2)

#### REFERENCES

- [1] Cunha SB da, Carneiro MC, Sa MM, Rodrigues A, Pina C. Neurodevelopmental Outcomes following Prenatal Diagnosis of Isolated Corpus Callosum Agenesis: A Systematic Review. *Fetal Diagn Ther.* 2021; 48(2):88–95.
- [2] Universidad Pedagógica y Tecnológica de Colombia, Aljure-Reales V de J, Rangel-Carrillo JJ, Universidad Pedagógica y Tecnológica de Colombia, Ramos JD, Universidad Pedagógica y Tecnológica de Colombia, et al. Agenesia del cuerpo calloso: un tema poco conocido. *Ces Med.* 2017;31(2):172–9.
- [3] Govil-Dalela T, Kumar A, Agarwal R, Chugani HT. Agenesis of the Corpus Callosum and Aicardi Syndrome: A Neuroimaging and Clinical Comparison. *Pediatr Neurol.* 2017 Mar 1;68:44-48.e2.
- [4] Gonçalves-Ferreira T, Sousa-Guarda C, Oliveira-Monteiro JP, Carmo-Fonseca MJ, Filipe-Saraiva P, Goulão-Constâncio A. [Corpus callosum agenesis]. *Rev Neurol.* 2003 Apr 16;36(8):701–6.

- [5] Francesco P, Maria-Edgarda B, Giovanni P, Dandolo G, Giulio B. Prenatal diagnosis of agenesis of corpus callosum: what is the neurodevelopmental outcome? *Pediatr Int Off J Jpn Pediatr Soc.* 2006 Jun;48(3):298–304.
- [6] Mangione R, Fries N, Godard P, Capron C, Mirlesse V, Lacombe D, et al. Neurodevelopmental outcome following prenatal diagnosis of an isolated anomaly of the corpus callosum. *Ultrasound Obstet Gynecol.* 2011;37(3):290–5.
- [7] Szczupak D, Kossmann Ferraz M, Gemal L, Oliveira-Szejnfeld PS, Monteiro M, Bramati I, et al. Corpus callosum dysgenesis causes novel patterns of structural and functional brain connectivity. *Brain Commun.* 2021 May 14;3(2):fcab057.
- [8] Mancuso L, Uddin LQ, Nani A, Costa T, Cauda F. Brain functional connectivity in individuals with callosotomy and agenesis of the corpus callosum: A systematic review. *Neurosci Biobehav Rev.* 2019 Oct;105:231–48.
- [9] Moutard M-L, Kieffer V, Feingold J, Lewin F, Baron J-M, Adamsbaum C, et al. Isolated corpus callosum agenesis: a ten-year follow-up after prenatal diagnosis (How are the children without corpus callosum at 10 years of age?): Isolated corpus callosum agenesis: a ten-year follow-up after prenatal diagnosis. *Prenat Diagn.* 2012 Mar;32(3):277–83.
- [10] Brown WS, Paul LK. The Neuropsychological Syndrome of Agenesis of the Corpus Callosum. *J Int Neuropsychol Soc.* 2019 Mar;25(3):324–30.
- [11] Popoola O, Olayinka O, Azizi H, Ojimba C, Khan T, Kallikkadan J, et al. Neuropsychiatric Manifestations of Partial Agenesis of the Corpus Callosum: A Case Report and Literature Review. *Case Rep Psychiatry.* 2019 Mar 25;2019:5925191.
- [12] Raile V, Herz NA, Promnitz G, Schneider J, Tietze A, Kaindl AM. Clinical Outcome of Children With Corpus Callosum Agenesis. *Pediatr Neurol.* 2020 Nov;112:47–52.
- [13] des Portes V, Rolland A, Velazquez-Dominguez J, Peyric E, Cordier M-P, Gaucherand P, et al. Outcome of isolated agenesis of the corpus callosum: A population-based prospective study. *Eur J Paediatr Neurol EJPN Off J Eur Paediatr Neurol Soc.* 2018 Jan;22(1):82–92.

**Citation:** Arturo Amed López-Márquez et al. "The Great Interhemispheric Connection. Could We Function without the Corpus Callosum? Systematic Review and Case Report", *ARC Journal of Clinical Case Reports (ARCJCCR)*, vol. 8, no.1, pp. 10-14, 2022. <http://dx.doi.org/10.20431/2455-9806.0801003>

**Copyright:** © 2022 Authors. This is an open-access article distributed under the terms of the Creative Commons Attribution License, which permits unrestricted use, distribution, and reproduction in any medium, provided the original author and source are credited.