

## Intratesticular Sertoli Cell Tumor: About a Case and Literature Review

Tarik Mhanna<sup>1,2\*</sup>, Anaour El Moudane<sup>1</sup>, Ciprian Frasinescu<sup>2</sup>, Ali Barki<sup>1</sup>

<sup>1</sup>Department of urology, Mohammed VI university medical center, Mohammed the first university Oujda, Morocco

<sup>2</sup>Service de chirurgie urologique, CHI Robert Ballanger, Aulnay-sous-Bois, France

**\*Corresponding Author:** Tarik Mhanna, Department of urology, Mohammed VI university medical center, Mohammed the first university Oujda, Morocco, Email: [yddoussalah.urob@gmail.com](mailto:yddoussalah.urob@gmail.com).

**Abstract:** Sertoli cell tumors (SCT) are very rare testicular tumors, representing 0.4% to 1.5% of all testicular malignancies. They are sub classified as classic, large-cell calcifying, and sclerosing Sertoli cell tumors. We report a case of a Sertoli cell tumor of the testis in a 37-year-old man. His chief complaint was a testicular pain right that he had during 4 months. Serum levels of tumor markers were within normal limits. Radical orchiectomy was performed.

Histopathology showed a Sertoli cell tumor with no evidence of malignancy. Through the observation and review of the literature which we will discuss the clinical and therapeutic features of this rare entity.

**Keywords:** Testicular, tumeur à cellules de Sertoli, orchidectomie. Testis.

### 1. INTRODUCTION

Tumours of the stroma and testicular sex cords account for 3-4% of all testicular tumours. Within this group, Sertoli cell tumours make up less than 1% of testicular tumours [1]. Only 10% of these tumours are metastatic and are considered malignant. They can be found at any age, but with a spike in frequency between 30 and 40 years. They occur in 40% of cases in a dysenteric context [2]. The most common clinical finding is a painless scrotal mass, with a third of the cases associated with gynecomastia and hormonal imbalance.

### 2. CASE REPORTS

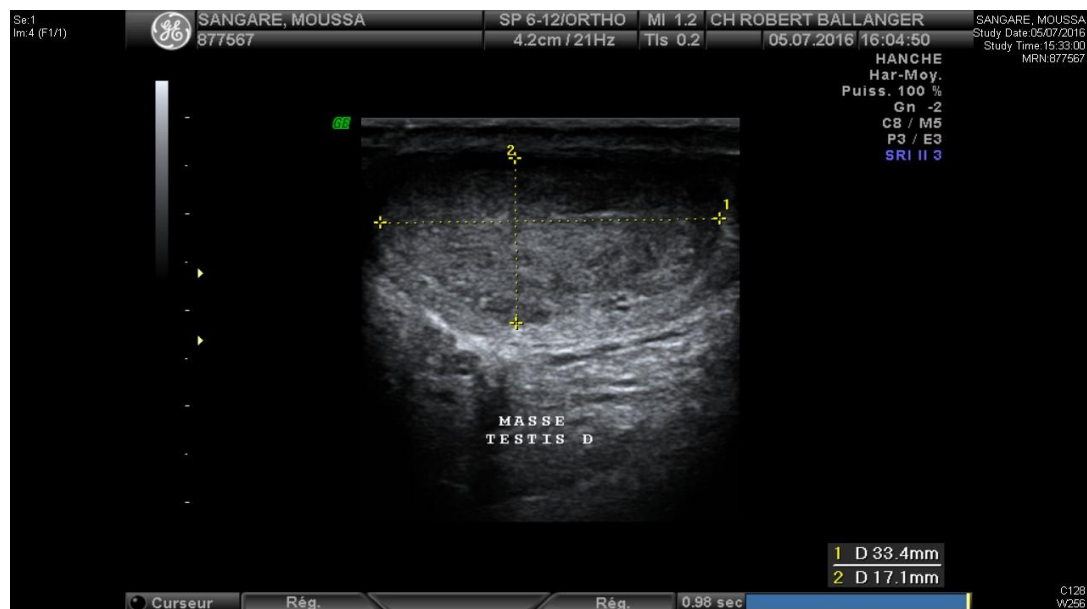
We report the case of a 37-year-old patient, who was admitted to our structure for treatment of right testicular pain that has been evolving for 4 months. The patient's history mainly included sickle cell disease.

Clinical examination revealed a left testicle of normal consistency, a straight testis increased in volume without palpable nodules but of much firmer consistency than on the left.

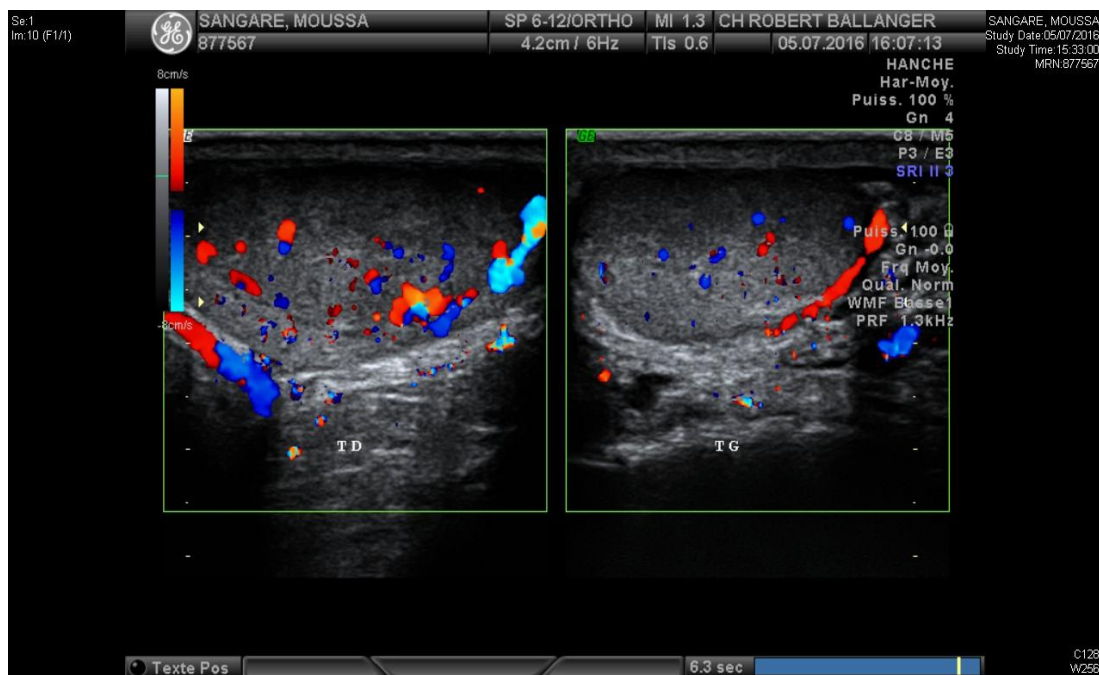
The scrotal ultrasound revealed this right intratesticular tissue lesion, of regular contours,

occupying almost the whole of the testicular parenchyma, measuring in its large dimensions 33.4 X 17 mm (Fig.1), this nodule is vascularized on the periphery and in the center (Fig.2). Left testicle and epididymis of strictly normal ultrasound appearance.

Tumor biomarkers ( $\alpha$ FP,  $\beta$ HCG, and LDH) were normal. We decided to do a thoraco abdominal CT that does not find metastasis at a distance, and two sperm samples for self-preservation at the CECOS level. Faced with these elements a right inguinal orchidectomy after clamping first cord was performed. The postoperative course was simple. The macroscopic anatomo-pathological examination showed a piece of orchidectomy comprising a cord and a testicle of 4.5 x 3.5 x 2 cm. At the cut, the testicular parenchyma contains a yellowish solid lesion discretely lobulated without necrotic or hemorrhagic reworking. This lesion, although limited, measures 2.8 x 2.1 cm and does not macroscopically infiltrate the epididymis, the tunica albuginea or the testile hilum. On microscopic examination it is a proliferation of diffuse architecture, lobulated or trabecular. This lesion consists of cubo-cylindrical cells with eosinophilic



**Figure1:** Ultrasound image showing a voluminous tissue nodular formation measuring 27 mm X 16 mm X 30 MM.



**Figure2:** Color Doppler ultrasound image hyper vascularized tissue lesion of the right testis on the periphery and in the center.

On microscopic examination it is a proliferation of diffuse architecture, lobulated or trabecular. This lesion consists of cubo-cylindrical cells with eosinophilic

Cytoplasm containing an oval nucleus, sometimes a little irregular, with a fine chromatin, without a prominent nucleolus. There are some nuclear atypias and rare mitoses. From the topographic point of view, the well-limited tumor is UN encapsulated remaining of strictly intra-testicular localization. The excision limits are healthy. The immunolabelings revealed reveal that the tumor cells express an intense labeling for calretinine and valentine.

Presence of a more discreet marking for Melan A. Proliferation index Ki 67: 5%.

In view of these aspects, the histological aspect and the immunohistochemical profile evoke a Sertoli cell tumor. The patient's file was discussed in the multidisciplinary oncology consultation; the decision was to perform simple monitoring.

### 3. DISCUSSION

Gonadal stromal cells and sex cords are derived embryologically from the genital crest [3]. There are different types of Sertoli cell tumors: Variant without further indication, sclerosing,

and high in lipids, large calcifying cells and malignant Sertoli tumors [4].

Sertoli cell tumors usually occur in post-pubertal subjects, mean age 45 years at the time of diagnosis [4]. But can occur at any age, including neonates. Although the development of most SCT occurs at normal testicle level, there are reported cases on cryptorchidic testicles [5].

SCT is usually sporadic but can occur in a dysgenetic context such as:

- The Carney complex, of autosomal dominant inheritance (PRKAR1 gene mutation), which variable associates cutaneous lentiginosis, myxomas, adrenocortical hyperplasia, pituitary adenoma, schwannoma.
- Peutz-Jeghers syndrome, of autosomal dominant inheritance (LKB1 / STK11 tumor suppressor gene mutation) involving cutanomucous lentiginosis, gastrointestinal hamartomatous polyps and increased susceptibility to different tumors;
- Androgen insensitivity syndrome [4].

The most common clinical manifestation in SCT is the slow and progressive development of painless testicular mass.

About one-third of the tumors in Sertoli cells are associated with gynecomastia, explained by the production of estrogens by tumor cells, but it is not clear that estrogen is produced by Sertoli cells or stromal cells [6]. In children, we can also see early pseudo-puberty.

From the anatomopathological point of view, the SCT presents itself macroscopically in the form of a nodular mass, uniform or multifocal with a very limited Appearance, firm and solid of whitish grey colour.

Microscopically: In well-differentiated tumors, SERTOLI cells are arranged in tubules separated by a fibrous stroma. The cells are arranged perpendicular to the axis of the tube. They have a cytoplasmic vacuolization realizing a micro-cystic aspect.

For its less differentiated forms, histological diagnosis can be difficult. One of the main criteria for the histological diagnosis of SCT is the ability of Sertoli cells to form tubes. From a phenotypic point of view, TCS show a marking with anti-cytokeratin

Antibodies, vimentine, EMA (epithelial antigen membrane) and sometimes NSE (neuron specific enolase)

The main histological differential diagnosis is represented by Leydig cell tumors, which also derive from sex cords and therefore have close architectural and cytological characteristics.

A large tumor, irregular margins, adjacent tissue invasion, lymphatic or vascular invasion and mitotic patterns usually indicate a malignant tumor of Sertoli cells, but the presence of metastasis is essential to prove that a tumor is clinically malignant [ 6.5].

Metastases can be late and have morphology different from the initial tumor (better or worse differentiation than the initial tumor) making their diagnosis sometimes difficult. They are ganglionic, retroperitoneal and visceral (lung, liver, bone) [7, 8]. Young and al [5] in their 3.8-year average follow-up of 16 patients with Sertoli cell tumors after radical orchiectomy; three of 12 patients who did not have metastases initially had metastases late. Histological, two of these three patients had micro vascular invasion, two with nuclear pleomorphism and necrosis in one patient.

The prognosis for a benign form of SCT is good, but the prognosis for malignant forms has not been well established. Metastatic tumors of Sertoli Cells have a poor prognosis; Godec [9] reported an average survival of 15 months after Diagnosis of metastasis in nine patients. The last cases of metastases reported in the literature occurred 10 years after a radical orchidectomy [10].

Kolon and al [11] suggested that a 5-year follow-up is necessary because of the characteristics of the tumor. In our case, we think that the prognosis of our patient will be good because of the small size of the mass, absence of histological abnormalities indicative of malignancy, and absence of evidence of metastatic localization. But close monitoring will be needed to detect late metastases.

Therapeutic management Repose on orchiectomy in benign forms, an enucleation could be considered. Complete excision of the lesion is necessary to establish the diagnosis.

In bilateral forms, unilateral orchiectomy with contralateral partial surgery is proposed. Retroperitoneal curettage is poorly documented in the literature. LINDEGAARD [12] on a series of 21 metastatic SCT reports 5 lesions.

Radiation therapy has not been proven effective in SCT.

Chemotherapy in metastatic SCT situations is not standardized; it relies on Cisplatin-based protocols by analogy with tumors of ovarian granulosa.

#### 4. CONCLUSION

Stromal Sertoli cell tumors and sex cords are rare. Malignancy, although exceptional, should be considered whenever there is a large tumor (greater than 5 cm) associated with cytonuclear

Polymorphism and significant mitotic activity. Orchiectomy is the treatment of choice.

#### REFERENCES

- [1] SNYDER H.M., D'ANGIO G.J., EVANS A.E., BEVERLY RANEY R: Neoplasms of the testis. In: Campbell's Urology, 6th Ed. Edited by P. C. Walsh, A. B. Retik, T. A. Stamey and E.D. Vaughan. Philadelphia, W. B. Saunders Co., 1992, pp. 1251-1252.
- [2] Kaluzny A, Matuszewski M, Wojtylak S, Krajka K, Cichy W, Plawski A, et al. Organ-sparing surgery of the bilateral testicular large cell calcifying sertoli cell tumor in patient with atypical Peutz-Jeghers syndrome. *Int Urol Nephrol* 2012; 44:1045—8.
- [3] PERITO P.E., CIANCIO G., and CIVANTOS F., POLITANO V.A.: Sertoli - Leydig cell testicular tumor: case report and review of sex gonadal stromal tumor histogenesis. *J. Urol*, 1992, 148, 883-885.
- [4] Sesterhenn IA, Jacobsen GK, Cheville J, Nistal M, Woodward PJ, Paniagua R, et al. In: Eble JN, Sauter G, Epstein JI, Sesterhenn IA, editors. World Health Organization. Classification of Tumours. Pathology and Genetics of Tumours of the Urinary System and Male Genital Organs. Lyon: IARC Press; 2004. p. 252—5.
- [5] Young RH, Koelliker DD, Scully RE. Sertoli cell tumors of the testis, not otherwise specified: a clinicopathologic analysis of 60 cases. *IS J Surg Pathol* 1998; 22:709-21?
- [6] Richie JP, Steele GS. Neoplasms of the testis. In: Wein AJ, Kavoussi LR, Novick AC, Partin AW, Peters CA, editors. *Campbell's urology*. 9th ed. Philadelphia: Saunders; 2007;893-935
- [7] De raeve H, Schoonooghe P, Wibowo R, Van Marck E, Goossens A. Malignant large cell calcifying Sertoli cell tumor of the testis. *Pathology* 2003; 199:113—7.
- [8] Peterson F, Bulimbasic S, Sima R, Michal M, Hora M, Malagon HD, et al. Large cell calcifying Sertoli cell tumor: a clinicopathologic study of 1 malignant and 3 benign tumors using histomorphology, immunohistochemistry, ultrastructure, comparative genomic hybridization, and polymerase chain reaction analysis of the PRKAR1A gene. *Hum Pathol* 2010; 41: 552—9.
- [9] Godec CJ. Malignant Sertoli cell tumor of testicle. *Urology* 1985; 26:185-8
- [10] Comperat E, Tissier F, Vieillefond A. Late metastasis after a testicular Sertoli cell tumor. *Ann Pathol* 2004; 24:45-6
- [11] Kolon TF, Hochman HI. Malignant Sertoli cell tumor in a prepubescent boy. *J Urol* 1997;15 8:608-9
- [12] LINDEGAARD-MADSEN E, MORCK-HULTBERG B. Metastatisizing Sertoli cell tumors of the human testis. A report of two cases and a review of the literature. *ACTA ONCOL* 1990, 29-7: 946.

**Citation:** Tarik Mhanna, Anaour El Moudane et.al, *Intratesticular Sertoli Cell Tumor: About a Case and Literature Review*, *ARC Journal of Clinical Case Reports*. 2019; 5(3): 21-24. doi:dx.doi.org/ 10.20431/2455-9806.0503004.

**Copyright:** © 2019 Authors. This is an open-access article distributed under the terms of the Creative Commons Attribution License, which permits unrestricted use, distribution, and reproduction in any medium, provided the original author and source are credited.