

Right Heart Failure and Hyperthyroidism: A Neglected Association

Safae Harrak^{1*}, Sanae El Arass², Meryem Nadif¹, Latifa oukerraj¹, Amri Rachida¹, Mohammed Cherti¹

¹Cardiology B Department. Ibn Sina Hospital, Rabat, Morocco

²Emergencies Department. Ibn Sina Hospital, Rabat, Morocco

***Corresponding Author:** Safae Harrak, Cardiology B Department. Ibn Sina Hospital, Rabat, Morocco, E-mail: harrak.safae27@gmail.com

Abstract

Background: Hyperthyroidism is a hyperkinetic syndrome related to an excess of circulating thyroid hormones. We report the case of a patient with Grave's disease who was admitted for right heart failure due to reversible thyrotoxic tricuspid regurgitation.

Case report: A 65-year-old patient, without medical history. He was admitted with dyspnea and bilateral leg edema. The examination revealed a tachycardia with signs of right heart failure. The electrocardiogram showed atrial fibrillation with an average ventricular rate of 112 beats per minute and low voltage in the frontal leads. Transthoracic echocardiography showed a very dilated right ventricle with a paradoxical septum motion. The tricuspid valve presents a lack of coaptation affecting the three leaflets which is responsible for massive tricuspid regurgitation. The inferior vena cava was dilated without collapse. Biological testing showed a very low thyroid-stimulating hormone (<0.003) and a high T4 and T3. Immunological testing confirmed Grave's disease. Our treatment approach was built on diuretics and treating hyperthyroidism with antithyroid drugs. We eliminated every etiology that would justify a functional tricuspid regurgitation. The evolution was marked by a regression of the congestive signs, a return to sinus rhythm after 40 days of treatment and a regression of both the tricuspid regurgitation and the dilation of the right ventricle nine months after antithyroid therapy.

Conclusion: This is a case of cardiothyreosis complicated by right heart failure caused by severe tricuspid regurgitation which is reversible under antithyroid therapy. We underline the advisability of carrying out a systematic thyroid assessment when presented with unexplained right heart failure.

Keywords: Tricuspid regurgitation, hyperthyroidism, atrial fibrillation, right heart failure.

1. INTRODUCTION

Hyperthyroidism is a hyperkinetic syndrome related to excess of circulating thyroid hormones. It may lead to cardiac involvement; cardiothyreosis. It is defined as an association of hyperthyroidism with severe heart abnormalities such atrial fibrillation. We report the case of a patient with grave's disease who was admitted for right heart failure due to reversible thyrotoxic tricuspid regurgitation.

2. MEDICAL OBSERVATION

A sixty-five-years old patient, without medical history. He was admitted to cardiac emergencies for progressive exertional dyspnea since 9 months with atypical chest pain that has been appeared since 2 months. He also reported an

increase in the volume of both lower limbs and permanent palpitations. The clinical examination led to cachexic patient, in poor general condition. Blood pressure was 110 / 70mmHg, cardiac frequency was at 110. The heart sounds were fast and irregular.

We noted signs of right heart failure; spontaneous turgor of the jugular veins, painful hepatomegaly and edema of the lower limbs. Pleuropulmonary examination was normal. The patient was also observed to have mild bilateral exophthalmos and goitreon palpation. The ECG recorded an atrial fibrillation with average ventricular rate at 112 bpm, ventricular extrasystole and low voltage in the frontal leads (see Figure 1).Chest X-ray revealed cardiomegaly at the expense of the right cavities

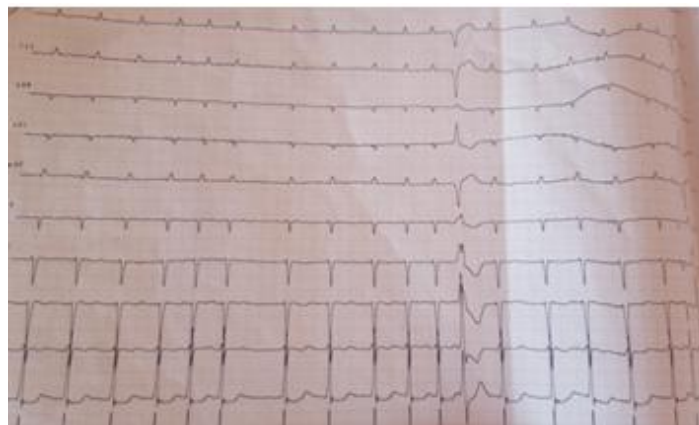


Figure1: *Electrocardiogram showing atrial fibrillation with average ventricular rate at 112 beats per minute, ventricular extrasystole and low voltage in the frontal leads*

The transthoracic echocardiography objectified a very dilated right ventricle (basal diameter at 54mm) with paradoxical septum (see figure2).

Tricuspid valve shows a lack of coaptation affecting the three leaflets which is responsible for massive tricuspid regurgitation (see figure 3).

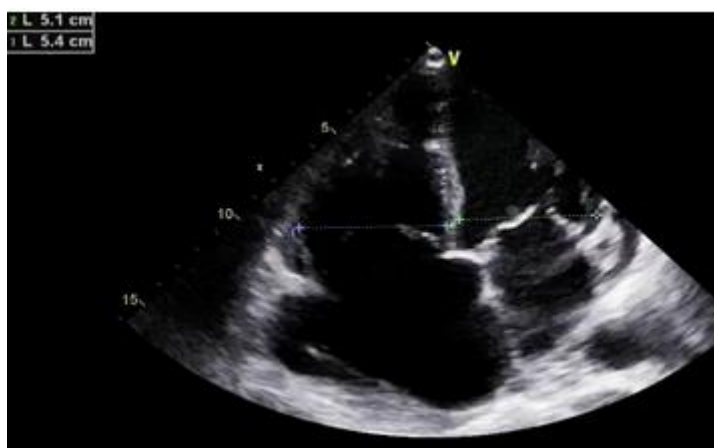

Figure2: *Significant expansion of right cavities*

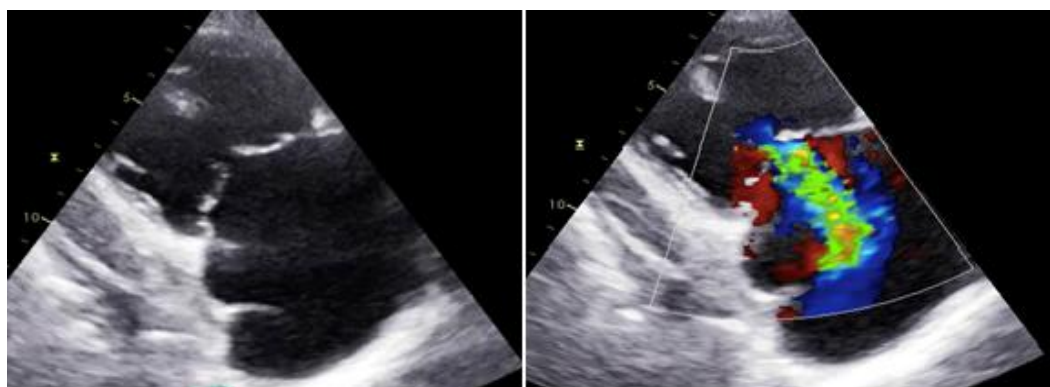


Figure3: *Tricuspid regurgitation by lack of coaptation of valve leaflets*

The inferior vena cava was dilated without collapse. The left ventricle is of normal size but with reduced left ventricular ejection fraction (LVEF). The right atrium more dilated than the left one (26cm² vs38cm²). Mitral regurgitation is mild. Mild pericardial effusion was also noted. The biological assessment showed a very low TSU (<0.003), and elevated T4 and T3. The diagnosis of pulmonary embolism was ruled out by performing DDimer dosage that was negativ.

The immunological assessment confirmed grave's disease. The cervical ultrasound showed a uniformly enlarged thyroid, suggesting thyroiditis. Our approach was to consider intravenous diuretics at a dosage of 250 mg / day using an electric syringe pump with potassium supplementation. We started Angiotensin converting enzyme (ACE) inhibitor and antialdosterone. The patient was ant coagulated once normalization of Time. To treat

hyperthyroidism, we have considered synthetic ant thyroid drug (carbimazol 40mg / day). The evolution was marked by resolution of signs of right heart failure under diuretics loop (went

from 53 kg to 44kg). After discharge, the patient has been followed during 9 months. Rhythm control was obtained after 40 days of synthetic antithyroid treatment (see Figure 4).

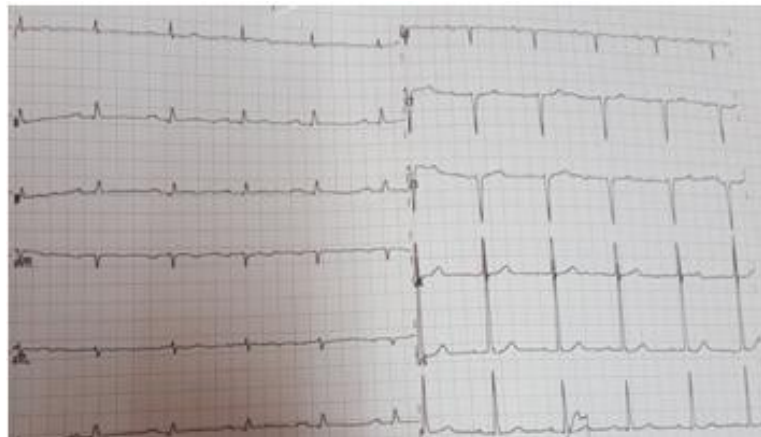

Figure4: *Electrocardiogram showing return to sinus rhythm after 40 days of synthetic antithyroid treatment*

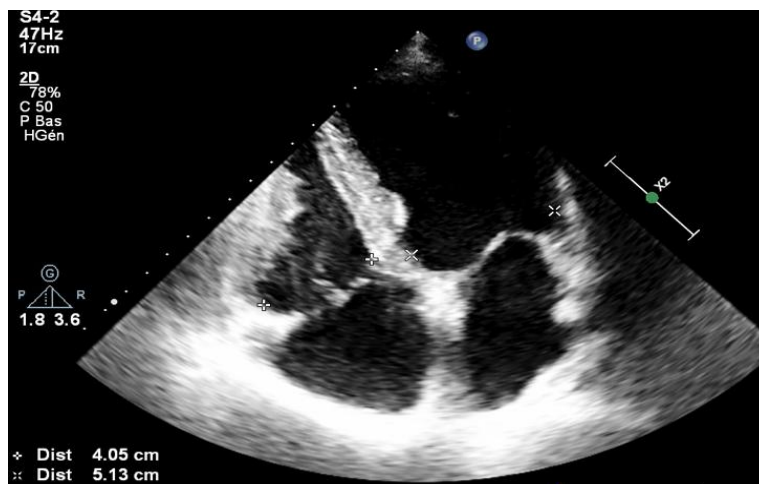

Figure5: *Regression of the dilation of right ventricle (Right-ventricular basal diameter went from 54mm to 40.5mm)*

	Before treatment	After 40 days	After 9 months
Right-ventricular basal diameter (mm)	54	50	40.5
ParadoxicalSeptum motion	Present	Absent	Absent
Right atrial area (cm ²)	38	30	23
Inferior vena cava	dilated without collapse	Normal with collapse	Normal with collapse
Tricuspid regurgitation	Massive with laminar flow	moderate	mild
SPAP(Pulmonary artery systolic pressure)	Pulmonary regurgitation flow not available Pulmonary velocity acceleration time (PVAT)= 50ms	50mmHg	23mmHg
Left ventricle end-diastolic diameter (mm)	52	50	50
Left atrial area (cm ²)	26	18	17
Left ventricular ejection fraction (LVEF)	Not calculated owing to the presence of paradoxical Septum motion	50%	56%
Pericardial effusion	Mild	Absent	Absent

Table1: *Evolution of echocardiographic parameters before treatment, 40 days and after 9 months of the treatment*

3. DISCUSSION

An excess of the thyroid hormones affects the cardiovascular system in various ways. We note a positive inotropic and chronotropic action of the heart that induces an increased cardiac output and venous return [1]. Peripheral vascular resistances are decreased [1]. Our patient was admitted for signs of right heart failure that were evolving in the context of hyperthyroidism. Right heart failure has been reported in some cases in the literature [1, 2, 3, and 4]. Which is related to tricuspid regurgitation and can be attributed to associated pulmonary hypertension. Tricuspid regurgitation is mainly caused by dilatation of the right ventricle secondary to tricuspid annulus dilatation [1]. During hyperthyroidism, several studies had reported dilatation and volume overload of right ventricular [4, 5]. Right ventricular is most involved and more sensitive to volumetric load due to its structure and thin wall [6].

Thyroid hormones increase right ventricular preload by increasing venous return which contributes to its dilation [7, 6]. Our patient exhibited a functional tricuspid regurgitation with structurally normal leaflets. Another mechanism of tricuspid regurgitation has been recently reported involving the dilatation of the tricuspid annulus secondary to atrial fibrillation in the absence of structural valve disease. It has been reported that, during atrial fibrillation, dilation of right atrium can induce dilatation of tricuspid annulus which is less fibrous and more expandable than the mitral annulus [8].

Pulmonary hypertension may coexist with hyperthyroidism and is characterized by its reversibility [9]. Under the effect of excess thyroid hormones, there is a decrease in pulmonary arterial resistance and an increase in pulmonary flow [10]. It may also lead to an increasing metabolism of some vasodilator substances [10]. Endothelial damage can occur as a result of Grave's disease either through increased lung flow or an autoimmune process [11]. In our case, it was difficult to evaluate pulmonary artery systolic pressure during the first transthoracic echocardiography. The systolic flow across the tricuspid valve was laminar and had a peak velocity of 1.11m/s. We couldn't have a pulmonary regurgitation flow. Nevertheless, the only parameter that supported pulmonary hypertension in our patient was a pulmonary velocity acceleration time (PVAT) of

50ms which became normalized during monitoring and treatment.

In contrast with hypothyroidism, pericardial effusion remains a rare complication of hyperthyroidism, which is common with Grave disease [12]. It is mainly caused by an autoimmune mechanism [13]. Pericardial effusion was thought to be linked to cardiothyreosis in our patient, but it could also have been related to congestive heart failure.

4. CONCLUSION

This is a case of cardiothyreosis complicated by right heart failure caused by severe tricuspid regurgitation which is reversible under antithyroid therapy. We underline the need to carry out a systematic thyroid assessment when presented with unexplained right heart failure.

REFERENCES

- [1] Hector F. Lozano, and Charu N. Sharma. Reversible Pulmonary Hypertension, Tricuspid Regurgitation and Right-sided Heart Failure Associated With Hyperthyroidism. *Cardiology in Review* • Volume 12, Number 6, November/December 2004
- [2] Xenopoulos N, Braden GA, Applegate RJ. Severe right heart failure in a patient with Graves' disease. *Clin Cardiol*. 1996;19:903–905
- [3] Dougherty MJ, Craige E. Apathetic hyperthyroidism presenting as tricuspid regurgitation. *Chest*. 1973;63:767–772
- [4] Iranzo Vasquez D, Rius Riu F, Pizarro Lozano E, et al. Severe tricuspid regurgitation as the main manifestation of hyperthyroidism. *Rev Esp Cardiol*. 1997;50:65–66
- [5] Braunwald E. Valvular heart disease. In Braunwald E, Zipes D, Libby P, eds. *Heart Disease: A Textbook of Cardiovascular Medicine*. Philadelphia, PA: W.B. Saunders Co; 2001:1691–1693
- [6] VanLiere EJ, Sizemore DA, Hunell J. Size of cardiac ventricles in experimental hyperthyroidism in the rat. *Proc Soc Exp Bio Med*. 1969; 132:663–665
- [7] Keniel Pierre, Sushee Gadde, Bassam Omar, G. Mustafa Awan, Christopher Malozzia . Thyrotoxic Valvulopathy: Case Report and Review of the Literature. *Cardiol Res*. 2017;8(3):134-138
- [8] Kihara T, Gillinov AM, Takasaki K, Fukuda S, Song J-M, Shiota M, Shiota T. Mitral regurgitation associated with mitral annular dilation in patients with lone atrial fibrillation: an echocardiographic study. *Echocardiography* 2009;26:885e889
- [9] Okada M, Ota T, Okura H, et al. Pulmonary hypertension associated with refractory

- hyperthyroidism: A case report. *J Cardiol.* 2001; 37:277–283.
- [10] Arroliga A, Dweik RA, Rafanan A. Primary pulmonary hypertension and thyroid disease: Letter. *Chest.* 2000;118:1224
- [11] Badesch BD, Wynne MK, Bonvallet S, et al. Hypothyroidism and primary pulmonary hypertension: an autoimmune pathogenic link? *Ann Intern Med.* 1993; 119:44 – 46.
- [12] Cullen D, Munjal N, Chalal H, Ramgopal S, Tas E, Witchel S, et al. Pericarditis as the presenting feature of Graves' disease in a pediatric patient. *Pediatr Emerg Care* 2017; 33: 268-70.
- [13] Inami T, Seino Y, Goda H, et al. Acute pericarditis: unique comorbidity of thyrotoxic crisis with Graves' disease. *Int J Cardiol.* 2014; 171:e129–e130.

Citation: Safae Harrak, Sanae El Arass, Meryem Nadif, Latifa oukerraj, Amri Rachida, Mohammed Cherti, *Right Heart Failure and Hyperthyroidism: A Neglected Association.* *ARC Journal of Cardiology.* 2020; 6(1): 13-17. doi:dx.doi.org/ 10.20431/2455-5991.0601004.

Copyright: © 2020 Authors. This is an open-access article distributed under the terms of the Creative Commons Attribution License, which permits unrestricted use, distribution, and reproduction in any medium, provided the original author and source are credited.