

Morphometric and morphologic characteristics of *Demodex bovis* and *Demodex ghanensis* (Acarina: Trombidiformes: Demodicidae) isolated from cattle in the Sudan

Mukhtar Taha Abu-Samra, Yassir Adam Shuaib*

College of Veterinary Medicine (CVM), Sudan University of Science and Technology (SUST), P.O. Box: 204 (Hilat Kuku), Khartoum North, the Sudan

*Corresponding Author: Yassir Adam Shuaib, College of Veterinary Medicine (CVM), Sudan University of Science and Technology (SUST), P.O. Box: 204 (Hilat Kuku), Khartoum North, the Sudan, Email: vet.aboamar@gmail.com, yassershaueb@sustech.edu

Abstract: *Demodex bovis* and *D. ghanensis* were isolated from cattle showing simultaneous hide and meibomian gland demodicosis. The two mites were subjected to morphologic and morphometric studies and compared. A small amount from each sample was placed on a slide and few drops of 10% potassium hydroxide were added to sample and gently heated for few minutes on a slide heater. Slides were examined under a microscope fitted with a camera and under a microscope fitted with an eyepiece lens micrometer. *D. bovis* was elongate, gently tapered and cigar-shaped while *D. ghanensis* mite was long, slender and gradually tapered to a sharp pointed terminus. *D. bovis* was wider but much shorter than *D. ghanensis*. The gnathosoma of *D. bovis* was roughly trapezoidal in shape, however, that of *D. ghanensis* was sub-rectangular. The epimeral plates were indistinct meeting smoothly at the midline in *D. bovis* and were conspicuous and longer than wide in *D. ghanensis*. The legs of *D. bovis* were stumpy with three short segments. Only the first three pairs of legs were slightly projecting outside the lateral surface of the body when *D. bovis* was viewed from the dorsal surface, but in *D. ghanensis*, the four pairs of legs were projecting outside the lateral surface of the body and directed forwards. The opisthosoma was gradually tapered to a rounded terminus and transversely striated in *D. bovis* and in *D. ghanensis* it was cylindrical, with faint annulations and gradually tapered to a sharp pointed terminus. The proctodeal pore of *D. bovis* was a sac-like structure compressed dorso-ventrally and in *D. ghanensis*, it was absent. The ova were oval and ellipsoid in *D. bovis* and *D. ghanensis* respectively. Distinct morphological differences were observed between the two mites in the shape of the gnathosoma, podosoma and opithosoma, epimeral plates, legs, shape and position of genital organs, and ova. The morphometric and morphologic characteristics of *Demodex* species other than *D. bovis* and *D. ghanensis* isolated from domestic animals in the Sudan should be investigated.

Keywords: *Demodex*; Morphometric and Morphologic characteristics; Cattle; Sudan

1. INTRODUCTION

The genus *Demodex* belongs to the family Demodicidae of the sub-order Trombidiformes of the order Acarina of the class Arachnida of the phylum Arthropoda (Soulsby, 1982). Among the numerous species of this genus, only few were reported to be of medical and veterinary concern (Nutting, 1976; Jarmuda *et al.*, 2012). Most of the known species of the genus *Demodex* are named after their hosts and are host specific (Soulsby, 1982; Radostits *et al.*, 2007; Takle *et al.*, 2010; Brener *et al.*, 2013; OIE, 2016). The occurrence of more than one species of *Demodex* infesting the same host (synhospitalic co-existence) has been observed

in some species of animals and in human. These different species of mite usually have different habitats (Slingenbergh *et al.*, 1980; Bukva, 1986; Baima and Sticherling 2002; Bikowski and Del Rosso 2009; Fantahun *et al.*, 2012; Mathison and Pritt, 2016; Izdebska and Rolbiecki, 2016).

Morphologic and morphometric characteristics of *D. bovis* and *D. ghanensis* were investigated during 1970s (Bukva, 1986; Izdebska, 2009; Baima and Sticherling, 2002; OIE, 2016). Adult *Demodex* mites display unique morphological features and are elongate, spindle-shaped, or vermiform mites. The length of the body of *Demodex* mites is between 250 and 850 μ m

(OIE, 2016; Izdebska and Rolbiecki, 2016). Mouthparts, legs, coxal fields and other body parts of many species of *Demodex* mites isolated from human beings, house and farm animals as well as wildlife were fully described and differences have been observed (Jarmuda *et al.*, 2012; OIE, 2016; Izdebska and Rolbiecki, 2016). However, morphological features of *Demodex* mites from the Sudan have never been investigated previously. Therefore, the present study is aiming at investigating and comparing the morphometric and morphologic characteristics of *D. bovis* and *D. ghanensis* isolated from cattle in some parts of the Sudan.

2. MATERIALS AND METHODS

2.1. Study Animals and Samples

The clinico-pathological features of demodicosis in the study animals have been fully described (Abu-Samra and Shuaib, 2014a; Abu-Samra and Shuaib, 2014b; Abu-Samra and Shuaib, 2015). Samples of fresh infected purulent materials were extracted and collected from nodules and pustules of 300 cattle (Fig. 1) among which 218 animals had simultaneous skin and meibomian gland lesions (Fig. 2).




Figure1. A cow showing numerous demodectic mange nodules mainly involving the lower half of the animal's body



Figure2. Simultaneous skin and meibomian gland demodicosis. Note wrinkling and folding of the skin, swelling of the eyelids and nodules on the upper eyelid arranged in a linear fashion

2.2. Laboratory Investigations

A small piece from each specimen of the infected purulent material was crushed between two microscope slides and examined. Individual mites were isolated and permanently mounted under a coverslip following the technique described by Abu-Samra *et al.* (1984). Another small amount of the infected purulent material from each animal was placed in the middle of a clean microscope slide and 2-3 drops of 10% potassium hydroxide were added, gently heated for five minutes on a slide heater, covered with a coverslip and examined under a microscope fitted with a camera (BHA Olympus, Japan). Another sample from the same specimens was placed in a watch glass flooded with 10% potassium hydroxide and left on the bench at room temperature for 15 minutes, after which period the infected material was teased with a pair of dissection needles until a homogenous material was obtained. A dropper was used to transfer a drop of the homogenous material to the middle of a clean microscope slide. The slide was allowed to heat gently on a slide heater for five minutes, covered with a coverslip and the excess fluid was removed with the edge of a filter paper. These preparations and the permanently mounted mites were examined under a microscope fitted with an eyepiece lens micrometer which was calibrated with a stage piece micrometer, and the measurements were recorded in μm . The identity of *D. bovis* mites was confirmed by plotting a graph of the total length (μm) of 100 female mites in infected material from different animals. The preparations from skin and meibomian gland lesions were also mounted on an overhead projector microscope with a screen (Leitz, Wetzlar, Germany) and the mites were traced on a white sheet of paper and retraced on tracing paper. The body of traced *D. bovis* and *D. ghanensis* was divided in various tagmata (Figs. 3 and 4). The gnathosoma, podosoma, opisthosoma and ova of the two species of mites were measured in 30 specimens of each of *D. bovis* and *D. ghanensis* for the purpose of comparison. The means and standard deviations of measurements in (μm) were conducted and recorded (Table 1).

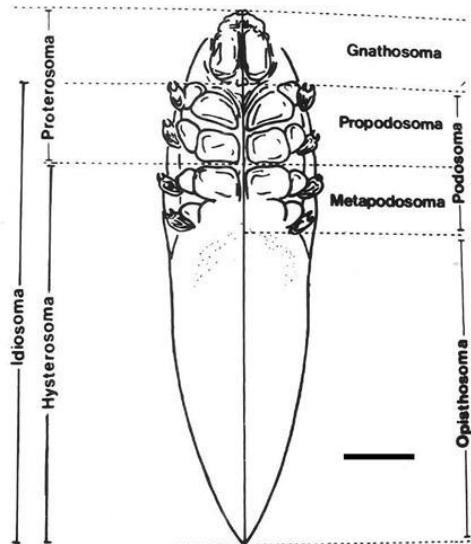


Figure3. Illustrated tracing of *Demodex bovis* mite isolated from purulent material extracted from skin lesions of bovine demodicosis. Overhead projector microscope, Scale bar: 30 μ m

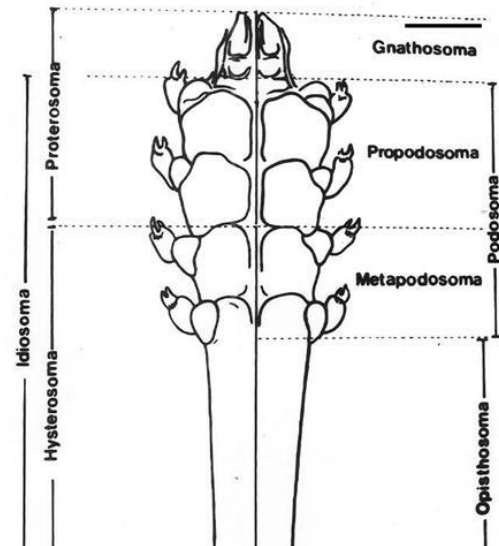


Figure4. Illustrated tracing of *Demodex ghanensis* mite isolated from caseous material extracted from meibomian gland lesions of bovine demodicosis. Overhead projector microscope, Scale bar: 30 μ m

Table1. Means and Standard Deviations of Measurements (μ m) of *Demodex bovis* and *D. ghanensis* (30 Specimens each)

Tagmata Measured (μ m)	<i>Demodex bovis</i>		<i>Demodex ghanensis</i>		
	Male	Female	Male	Female	
Gnathosoma	Length	38.88 \pm 2.18	37.22 \pm 3.82	29.27 \pm 1.46	28.34 \pm 1.25
	Width	36.56 \pm 1.12	35.42 \pm 1.89	32.21 \pm 1.38	32.05 \pm 1.04
Podosoma	Length	80.84 \pm 7.68	73.02 \pm 5.81	128.87 \pm 4.38	129.81 \pm 4.14
	Width	72.91 \pm 2.99	69.44 \pm 4.31	58.05 \pm 1.07	57.22 \pm 1.56
Opisthosoma	Length	152.1 \pm 13.8	128.8 \pm 11.34	288.88 \pm 14.9	274.6 \pm 17.32
	Width	58.12 \pm 3.04	56.23 \pm 1.31	46.16 \pm 6.04	44.77 \pm 2.92
Total Length		271.8 \pm 10.9	239.0 \pm 12.1	447.0 \pm 16.6	432.8 \pm 15.0
Ovum	Length	85.27 \pm 3.96		138.89 \pm 5.24	
	Width	52.68 \pm 5.04		55.55 \pm 2.93	

3. RESULTS

Numerous *Demodex* mites and their different developmental stages were seen in crushed purulent material expressed from skin lesions (Fig. 5) and meibomian gland lesions. *D. bovis* (Fig. 6) and *D. ghanensis* (Fig. 7) were successfully isolated and identified. In all specimens, male *Demodex* mites were less in occurrence than females.

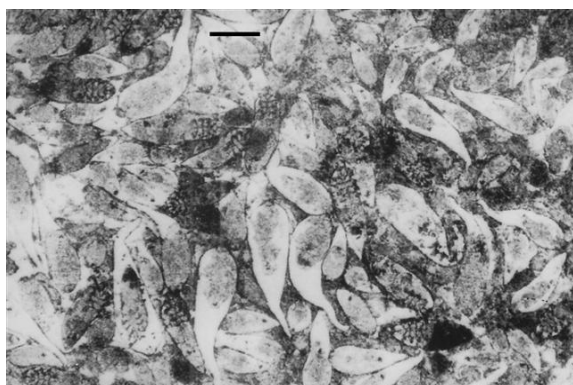


Figure5. Crushed purulent material extracted from skin lesions of bovine demodicosis. Note: numerous *Demodex bovis* mites and their different developmental stages. Scale bar: 160 μ m

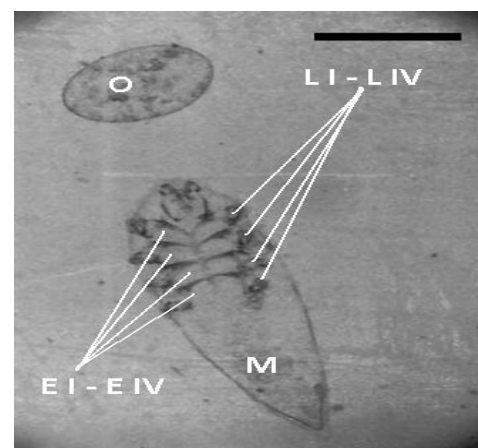


Figure6. Ventral view of female *Demodex bovis* (M), showing indistinct epimeral plates (E I - E IV) and four stumpy legs (L I - L IV) and (O) ovum of *D. bovis*. Scale bar: 50 μ m

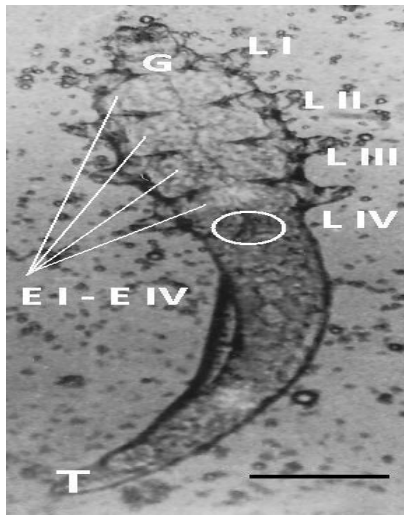


Figure7. Ventral view of Female *Demodex ghanensis* mite, showing a sub-rectangular gnathosoma (G), conspicuous epimera (E I – E IV), four projecting legs (L I – L IV), vulva (circle) and sharp pointed terminus (T). Scale bar: 45 μm

3.1. *Demodex bovis*

The identity of *D. bovis* was confirmed by graphic representation (Fig. 8) of the total length in μm of 100 female mites. These mites were elongate gently tapered and cigar-shaped (Figs. 3 and 6). The adult males of *D. bovis* (Fig. 9) were longer and wider than the female (Fig. 6) mites and were 272 μm in length and 73 μm in width. The adult females of *D. bovis* were 239 μm in length and 69 μm in width (Table 1). In male mites the gnathosoma was 14%, podosoma 30% and opisthosoma 56% of the total body length, while in female mites the gnathosoma was 16%, podosoma 31% and opisthosoma 54% of the total body length.

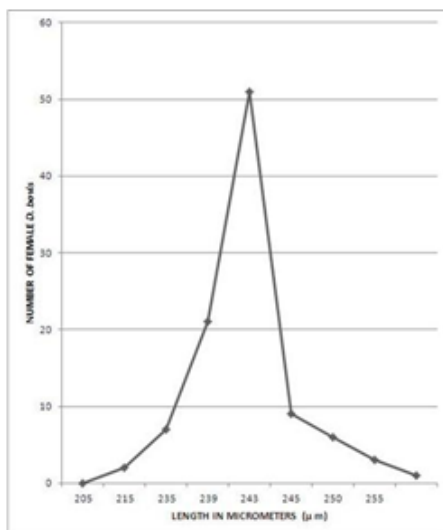


Figure8. Graphic representation of the lengths in (μm) of 100 female *Demodex bovis* mites in purulent material extracted from skin lesions of bovine demodicosis in different animals

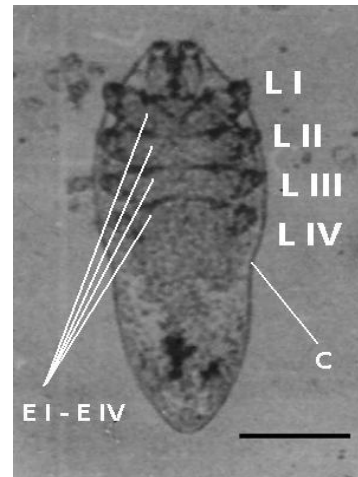


Figure9. Ventral view of male *Demodex bovis* mite, showing indistinct epimeral plates (E I – E IV) and four stumpy legs (L I – L IV). Note characteristic constriction posterior to epimera IV (C). Scale bar: 60 μm

The gnathosoma of *D. bovis* was roughly trapezoidal in shape (Figs. 3, 6 and 9), and wide at the base. Dorsal view of the gnathosoma revealed a spatula shaped epistome situated between two roughly triangular-shaped segments of the capitulum. The supracoxal spines were directed medially and bifurcated distally. Ventral view of the capitulum showed that it was roughly conical bearing a rectangular shaped lower jaw plate with the mouth opening at its distal end. Coxa of palps and palps with two free segments were also seen. The proximal segment was salient, and the distal segment showed palp setae. The dorsum of the podosoma showed fingerprint-like inscriptions. An antero-dorsal view of the gnathosoma and frontal view of the capitulum revealed a rectangular epistome hanging over the mouth, and covering the chelicerae and labial sheath of chelicerae. The two segments of palp were rounded in outline and compressed antero-posteriorly. The proximal segment was salient and the distal segment II bears 5-6 distinct finger-like palp setae. The first three pairs of legs were slightly projecting outside the lateral surface of the body, while the fourth pair were shorter and were not projecting from the lateral surface when the mite was viewed from the dorsal surface (Figs. 3, 6 and 9). However, all four legs could be seen when the mite was viewed from the lateral surface. The epimeral plates were indistinct meeting smoothly at the midline. The legs were stumpy with three short segments and the third distal segment bearing a pair of short equal claws. The body of male *D. bovis* was slightly constricted posterior to epimera IV (Fig.

9). The male genital organ (adeagus) is situated in an oval-shaped shield on the mid-dorsal surface at the level of epimeral plate II. The adeagus had a bulb-like tip and was slightly deviated to the left of the mid-line. The female genital organ (vulva) is a longitudinal slit opening just behind the arched posterior margin of epimeral plate IV. The opisthosoma of *D. bovis* was transversely striated and gradually tapering to a rounded terminus. The striations meet at the terminus in an elliptical fashion. The opisthosomal organ (proctodeal pore) was situated mid-ventrally and about 30 μm from the opisthosomal terminus and it is a sac-like structure compressed dorso-ventrally.

The ova of *D. bovis* were oval in shape (Fig. 6), and were 85 μm in length and 53 μm in width.

3.2. *Demodex Ghanensis*

Examination of crushed caseous infected material from meibomian gland lesions revealed similar findings as in specimens from skin lesions, nevertheless, *D. ghanensis* mites and their different developmental stages were much less than those seen in infected material from skin lesions.

The *D. ghanensis* mite is an elongate slender mite (Fig. 4 and 7). The adult male was slightly longer, but of nearly the same width as the female; 447 μm in length and 58 μm in width. Female mites were 433 μm in length and 57 μm in width (Table 1). The gnathosoma was 7%, the podosoma was 29%, and the opisthosoma was 65% of the total length of male *D. ghanensis*. In females the gnathosoma was 7%, the podosoma was 30% and the opisthosoma was 63% of the total length of the mite. *D. ghanensis* has a sub-rectangular gnathosoma (Figs. 4 and 7). The male podosoma was slightly shorter, but broader than females, and the opisthosoma in the male was longer and wider than females (Table 1). The epimeral plates were conspicuous and were longer than wide (Fig 7). The first pair of epimeral plates were partially fused, the second and third were not fused and the fourth were markedly fused forming an inverted V-shaped space posteriorly. The female genital opening (vulva) is a narrow slit lying between the inverted V-shaped space (Fig. 7). The male genital organ (adeagus) had a flame-like tip situated dorsally at the mid-line and extending between the third and fourth epimera and anteriorly to the middle of the second epimera. The four pairs of legs were projecting outside the lateral surface of the body and were pointing

forwards with distinct claws on segment three (Figs. 4 and 7). The opisthosoma was cylindrical and slender, with faint annulations and gradually tapered to a sharp pointed terminus (Fig. 7). The opisthosomal organ (proctodeum) was absent in both sexes.

The ova of *D. ghanensis* were ellipsoid in shape and were 139 μm in length and 56 μm in width (Table 1).

4. COMPARISON OF THE TWO SEXES

4.1. *Demodex Bovis*

Male *D. bovis* could easily be distinguished from females by the constriction of the body posterior to epimera IV and by being longer and wider than females. However, in male mites the percentage of the length of the gnathosoma and podosoma of the total body length was less than the percentage in females, while the percentage of the length of the opisthosoma to the total body length was higher in males than in females.

4.2. *Demodex Ghanensis*

Male *D. ghanensis* mites were longer and slightly wider than females. The percentage of the gnathosoma of both sexes to the total body length is equal, but in females the percentage of the podosoma length to the total body length is higher than in males. The percentage of the opisthosoma is slightly higher in males than in females. The male podosoma was slightly shorter, but broader than in females.

Comparison of *Demodex bovis* with *Demodex ghanensis*

Great differences were noticed between the morphometric data, morphologic characteristics and body configuration of the two mites. *D. ghanensis* was long, slender and gradually tapered to a sharp pointed terminus, while *D. bovis* was elongate, gently tapered and cigar-shaped. *D. bovis* was wider but shorter than *D. ghanensis*. The gnathosoma of *D. bovis* was roughly trapezoidal in shape, whereas that of *D. ghanensis* was sub-rectangular. In *D. bovis*, the epimeral plates were indistinct meeting smoothly at the midline. In *D. ghanensis*, the epimeral plates were conspicuous and were longer than wide. The first pair of epimeral plates in *D. ghanensis* were partially fused, the second and third were not fused and the fourth were markedly fused forming an inverted V-shaped space posteriorly. In *D. bovis*, the legs were stumpy with three short segments and the third distal segment bearing a pair of short equal

claws. In *D. bovis*, only the first three pairs of legs were slightly projecting outside the lateral surface of the body, and the fourth pair of legs were shorter and were not projecting from the lateral surface of the body when viewed from the dorsal surface. In *D. ghanensis*, the four pairs of legs were projecting outside the lateral surface of the body, were directed forwards, with distinct claws on segment three. The male genital organ (adeagus) in *D. bovis* is situated in an oval-shaped shield on the dorsal surface at the midline, had a bulb-like tip and was slightly deviated to the left of the mid-line, while that of *D. ghanensis* had a flame-like tip situated dorsally at the mid-line and extending between the third and fourth epimera and anteriorly to the middle of the second epimera. In *D. bovis*, the female genital organ (vulva) is a longitudinal slit opening just behind the arched posterior margin of epimeral plate IV, while in *D. ghanensis* the vulva is a narrow slit lying between the inverted V-shaped space formed by fusion of the fourth epimera. In *D. bovis*, the opisthosoma was gradually tapered to a rounded terminus and transversely striated. The striations meet at the terminus in an elliptical fashion but in *D. ghanensis* the opisthosoma was cylindrical with faint annulations and gradually tapered to a sharp pointed terminus. In *D. bovis*, the opisthothomal organ (proctodeal pore) was a sac-like structure compressed dorso-ventrally, and situated mid-ventrally about 30 μm from the opisthosomal terminus whereas in *D. ghanensis* the proctodeum was absent in both sexes. In *D. bovis*, the ova were oval in shape and in *D. ghanensis* the ova were ellipsoid.

5. DISCUSSION

In this study *D. bovis* and *D. ghanensis* were isolated from demodectic skin and meibomian gland lesions of the same animals. This finding was of interest and was subjected to speculation. The possible explanation of this finding was that each species of the two mites is morphologically adapted to suit the confines of its habitat. Additionally, each of the two species possesses distinct anatomical structures to be able to pave their way through their habitat, become well established, and reproduce. Izdebska (2009) indicated that some particular hosts are parasitized by synhospitalic species which are host-specific but usually parasitize different areas of the skin. On the other hand, Oppong (1970), Nutting (1976), Slingenbergh et al. (1980), Bukva (1986), Bima and Sticherling (2002), Bikowski et al. (2009), and Izdebska (2009)

reported the occurrence of more than one species of *Demodex* mites in the same parasitized area (meibomian gland or skin) in different animal species and human. While Nemeseri and Sezeky (1966) reported the occurrence of one species of mite in different habitats including meibomian glands, hair follicles and sebaceous glands and epithelial tissue of the sensory hairs of the same host. This was observed in sheep that were infested with *D. ovis*. Apart from seemingly being host specific, demodicids also show remarkable adaptation to match their unique environment (Nutting, 1976; Radostits *et al.*, 2007). The results obtained in the current investigation indicated that the body configuration of *Demodex* mites is adaptational and is strongly related to the nutritional requirement of the mite and the anatomical structure of its habitat.

In this study, the total average length of male and female *D. bovis* mites was from 272 to 239 μm and the total average width was between 73 and 69 μm . Nemeseri and Szeky (1961), Desch and Nutting (1972), Bukva (1986) and Soulsby (1982) reported that the average length and width of *D. bovis* varied from 215 to 270 and from 55 to 70 μm , respectively. In contrast to the findings of the present study, Hiepe and Ribbeck (1982) reported that the length of male *D. bovis* mites was shorter than females but of similar width. The length of male mites ranged from 220 to 245 μm and width ranged from 58 to 67 μm , while the length of female mites ranged from 212 to 258 μm and width ranged from 54 to 66 μm . Variations in the measurements of the ova were also observed. In this study, the length and width of the oval-shaped ovum were 85 and 53 μm , respectively. Desch and Nutting (1972) indicated that the mean length and width of the ovum were 79 and 40 μm . On the other hand, Nemeseri and Szeky (1961) and Hiepe and Ribbeck (1982) reported that the length and width of the ovum were twice more than the length and width reported herein. This observation could likely be related to the co-existence of synhospitalic *Demodex* mites. Also, some of the numerous records of mites and associated clinical symptoms which have been ascribed to *D. bovis* may, in fact, pertain to other *Demodex* species. The relatively longer measurements recorded in this study for *D. bovis* in comparison to the ones recorded by Desch and Nutting (1972) and Bukva (1986) could be attributed to adaptation of the mite to suit the confines of its habitat as the infected

specimens were obtained from Zebu cattle which have well developed pilosebaceous units to be able acclimatize with the harsh and hot environmental conditions of the tropics.

Morphometric studies of *D. ghanensis* revealed that male and female mites were 447 and 433 μm in length and 58 and 57 μm in width respectively. Oppong et al. (1975) found that the total length of male and female mites were 449 and 432 μm . Moreover, the size of the ellipsoid ovum reported in the present study (139 μm in length and 56 μm in width) was a little different from the one reported by Oppong et al. (1975) who reported a length of 145 μm and a width of 54 μm . These minor differences recorded in the measurements of the different tagmata between this study and the findings of Oppong et al. (1975) could possibly be related to human factors; measurements being conducted in different laboratories.

In the current study, *D. bovis* and *D. ghanensis* were isolated from a large number of cattle showing severe clinical signs and symptoms, extensive gross lesions, and marked histopathological changes compatible with cell mediated immunity involving the skin and meibomian glands of cattle (Abu-Samra and Shuaib, 2014a; Abu-Samra and Shuaib, 2014b; Abu-Samra and Shuaib, 2015). Only *D. bovis* and only *D. ghanensis* were isolated from skin and meibomian glands, respectively. Moreover, the identity of *D. bovis* was confirmed by a graphic representation of the measurements of the total length of 100 female mites, and the identification of both mites were confirmed by reference laboratories. All these factors make this study superior to previous investigations in which no clinical signs or gross lesions were observed or in many cases of eyelid infestations, the species of the mites involved were undetermined.

In spite of the long and slender body of *D. ghanensis* which conformed with its complicated branched tubular habitat in the meibomian gland, the infected material extracted from the lesions showed much less infestation in comparison with the large numbers of *D. bovis* mites in infected material extracted from skin lesions. This could probably be due to the constant sebum flow from the meibomian gland that may lead to expelling of *D. ghanensis* mites at the first stages of development (ovum and inactive moulting stages) as has been noted in *D. flagellurus* mites

infestation in the house mouse (*Mus musculus*) where sebum flow from the preputial and clitoral glands resulted in the expulsion of the ova and inactive moulting stages between the developmental intervals of *D. flagellurus* mites (Bukva, 1985).

In all specimens, male *Demodex* mites were less in occurrence than females. This was attributed to the fact that fertilization took place on the skin surface, and male mites died few days after copulation, while female mites moved back in the hair follicles depositing their eggs. This finding substantiated the findings of Nemeseri and Szeky (1961) and Spickett (1961) who also reported that male *Demodex* mites were less in occurrence than females, and attributed this to the short life-span of male mites.

In summary, many distinct and clear morphological variations were observed between *D. bovis* and *D. ghanensis* mites in different parts of the body including the shape of the gnathosoma, podosoma and opithosoma, epimeral plates, legs as well as in the shape and position of genital organs. The ova of the mites were also different in shape and size. Male and female mites could easily be distinguished by the constriction of the body posterior to epimera IV and body length in case of *D. bovis*. In case of *D. ghanensis*, male mites were longer and wider than female mites and the percentage of the gnathosoma of both sexes to the total body length is equal. The morphometric and morphologic characteristics of *Demodex* species other than *D. bovis* and *D. ghanensis* isolated from domestic animals in the Sudan should be investigated. Additionally, molecular characterization of the *Demodex* species besides to *D. bovis* and *D. ghanensis* is warranted.

ACKNOWLEDGEMENTS

The authors are indebted to the Agricultural Research Council, National Council for Research, Khartoum, Sudan, for the generous support of this work. Dr. W. N. Beesley, formerly Head/ Department of Veterinary Parasitology, Liverpool School of Tropical Medicine, UK, is gratefully acknowledged for his interest in this work and for the confirmation of the identification of *Demodex bovis* mites. The confirmation of the identification of *D. bovis* and *D. ghanensis* mites by the late professor W. B. Nutting, Department of Zoology University of Massachusetts, USA, is highly appreciated and acknowledged with thanks.

REFERENCES

- [1] Abu-samra M. T., Abdel Aziz M. A. R., and Salih A. K. M. M. (1984): A new technique for the isolation of *Demodex bovis* from preserved infected material. *Ann. Trop. Med. and Parasitol.*, 78: 319 – 321.
- [2] Abu-Samra M. T., and Shuaib, Y. A. (2014a): Bovine demodicosis: Prevalence, clinico-pathological and diagnostic study. *J. Vet. Adv.*, 4: 381 – 397.
- [3] Abu-Samra, M. T., and Shuaib, Y. A., (2014b): Meibomian gland demodicosis in cattle: The Clinical Disease and Diagnosis. *Inter. J. Vet. Sci.*, 3: 11-17.
- [4] Abu-Samra, M. T., and Shuaib, Y. A. (2015): Pathology and pathogenesis of bovine skin and meibomian gland demodicosis. *Revue d'élevageet de médecine vétérinaire des pays tropicaux*, 67(2), 77-85.
- [5] Baima B. and M. Sticherling (2002): Demodicidosis Revisited: Minireview. *Acta Dermato-Venereologica*, 82: 3–6.
- [6] Bikowski, J. B., and Del Rosso, J. Q. (2009): *Demodex dermatitis* a retrospective analysis of clinical diagnosis and successful treatment with topical Crotamiton. *J. Clin. Aesthetic Dermatol.*, 2: 20 –25.
- [7] Brener B., B. M. Palmeira, B. Bastos, V. M. Antunes, N. D. Silva, and P. R. Millar (2013): Presence of *Demodex bovis* in bovine feces: case report. *Vet. Not.*, Uberlândia, 19(1), 30-32.
- [8] Bukva, V. (1985): *Demodex flagellurus* SP. N. (Acari : Demodicidae) from preputial and clitoral gland of the house mouse, *Mus musculus* l. --- *Folia Parasitol.*, (Praha) 32: 73 – 81.
- [9] Bukva, V. (1986): *Demodex tauri* SP. N. (Acari : Demodicidae), A new parasite of cattle. *Folia Parasitol.* (Praha)., 33: 363 – 369.
- [10] Desch, C. E., and Nutting, W. B. (1972): Demodicids (Trombidiformes: Demodicidae) of medical and veterinary importance --- *Proc. 3rd. Internatl. Congress, Acarology* --- Prauge. P. 499-505.
- [11] Fantahun, T., Yigzaw, T., and Chanie, M. (2012): Bovine Demodecosis: Treat to Leather Industry in Ethiopia. *Asian J. Agric. Sci.*, 4: 314 – 318.
- [12] Hiepe, T., and Ribbeck, R. (1982): Familie Demodicidae - Haarbalgmilben, Gattung *Demodex*. *Lehrbuch der Parasitologie. Vet. Med. Prachno Entomol.*, 4: 96 – 104. (German).
- [13] Izdebska J. N. and L. Rolbiecki (2016): A new genus and species of demodecid mites from the tongue of a house mouse *Mus musculus*: description of adult and immature stages with data on parasitism. *Medical and Veterinary Entomology*, 1-9. doi: 10.1111/mve.12167
- [14] Izdebska, J. N. (2009): Selected aspects of adaptations to the parasitism of follicle mites (Acari: Demodecidae) from hoofed mammals. *European Bison Conservation Newsletter*. 2: 80 – 88.
- [15] Jarmuda S., O'Reilly N., Zaba R., Jakubowicz O., Szkaradkiewicz A., and Kavanagh K. (2012): Potential role of *Demodex* mites and bacteria in the induction of rosacea. *J. Med. Microbiol.*, 61(Pt 11): 1504-1510. doi: 10.1099/jmm.0.048090-0
- [16] Mathison B. A. and B. S. Pritt (2014): Laboratory Identification of Arthropod Ectoparasites. *Clinical Microbiology Reviews*, 27(1): 48–67.
- [17] Nemeseri, L., and Szeky, A. (1966): Demodicosis in sheep. *Acta Vet. Acad. Sci. Hung.* 16: 53 – 64.
- [18] Nemeseri, L., and Szeky, A. (1961): Demodicosis in cattle. *Acta Vet. Acad. Sci. Hung.*, 11: 209 – 221.
- [19] Nutting, W. B. (1976): Hair follicle mites (*Demodex* spp.) of medical and veterinary concern. *Cornell Vet.*, 66: 214 – 231.
- [20] OIE (2016): *Mange. OIE terrestrial manual*, Chapter: 2.7.9. World Organization for Animal Health, Paris, France, pp: 1-12.
- [21] Oppong, E. N.W., Lee, R. P., and Yasin, S. A. (1975): *Demodex ghanensis* Sp. nov. (Acari – Demodicidae) parasitic on West Africa cattle. *Ghana J. Sci.*, 15: 39 – 43.
- [22] Oppong, E. N.W. (1970): Aspects of bovine demodicosis, streptothricosis and besnoitiosis in the Accra plains of Ghana and a study of *Demodex ghanensis* Sp. n., [Phd Thesis], University of Dublin, U.K.
- [23] Radostits, O. M., Gay, C.C., Hinchcliff, K. W., and Constable, P.D. (Eds.) (2007): *Veterinary Medicine, A textbook of the diseases of cattle, horses, sheep, pigs and goats*. 10 th Edn., London and Saunders: Elsevier. p. 1608 – 1609.
- [24] Rak, H., and Rahgozar, R. (1975): Demodectic mange in the eyelids of domestic ruminants in Iran. *Bull. Soci. Pathol. Exotic.*, 68: 591 – 593.
- [25] Slingenbergh, J., Mohammed, A. N., and Bida, S.A. (1980). Studies on bovine demodecosis in northern Nigeria. *Vet. Q.*, 2: 90 – 94.
- [26] Soulsby, E. J. L., (Ed.), (1982): *Helminths, Arthropods and Protozoa of Domesticated*

- Animals. 7th Edn., London: Bailliere Tindall. p. 476 – 479.
- [27] Spickett, S. G. (1961): Studies on *Demodex folliculorum* Simon (1842) I. life history. Parasitol., 51: 181 – 192.
- [28] Takle, G. L., W. K. Suedmeyer, J. W. Mertins, and M. M. Garner (2010): Generalized demodecosis in three sibling, juvenile rock hyraxes (*Procavia capensis*). Journal of Zoo and Wildlife Medicine, 41(3): 496–502.

Citation: Mukhtar Taha Abu-Samra, Yassir Adam Shuaib, Morphometric and morphologic characteristics of *Demodex bovis* and *Demodex ghanensis* (Acarina: Trombidiformes: Demodicidae) isolated from cattle in the Sudan. *ARC Journal of Animal and Veterinary Sciences*. 2017; 3(4):25-33. doi: [dx.doi.org/ 10.20431/2455-2518.0304004](https://doi.org/10.20431/2455-2518.0304004).

Copyright: © 2017 Authors. This is an open-access article distributed under the terms of the Creative Commons Attribution License, which permits unrestricted use, distribution, and reproduction in any medium, provided the original author and source are credited.